

## Recurrence Rates Following External Valvular Stenting of the Saphenofemoral Junction: A Comparison with Simultaneous Contralateral Stripping of the Great Saphenous Vein

R.J. Lane,<sup>1,2,3,4\*</sup> M.L. Cuzzilla,<sup>1,4</sup> J.C. Coroneos,<sup>1</sup> M.N. Phillips<sup>3,4</sup> and J.T. Platt<sup>4</sup>

<sup>1</sup>Dalcross Private Hospital, <sup>2</sup>North Shore Private Hospital, <sup>3</sup>Royal North Shore Hospital, and <sup>4</sup>Vascular Specialists Investigations and Management, Sydney, New South Wales, Australia

**Objectives.** The incidence of recurrent varicose veins remains high despite the development of new ablative treatments for varicose veins associated with incompetence of the saphenofemoral junction. External valvular stenting (EVS) of the terminal and/or subterminal valves of the great saphenous vein (GSV) provides a reparative, physiological approach that requires long-term evaluation. The aim of this study was to compare recurrences following EVS with perforate invaginate (PIN) stripping of the GSV.

**Methods.** Included in the study were 193 patients (386 limbs) all of whom underwent simultaneous PIN-stripping of the GSV in one limb and EVS in the contralateral limb. Duplex scanning of the GSV and venous valves established suitability for each procedure. Only valves with visible, mobile cusps on ultrasound imaging are suitable for EVS. Stents were specifically designed Dacron reinforced silicone for left and right saphenofemoral junctions and for the subterminal valve. In a separate group of patients identified from a database where unilateral and bilateral stents had been implanted, 39 limbs with recurrent varices were examined clinically and ultrasonically to determine the aetiology of recurrences.

**Results.** Follow up was available to a maximum of 147 months. The total recurrence rate was 12.4%; stripping (22.2%) and EVS (4.6%) ( $P < 0.01$ ). The residual reflux as measured by postoperative Valsalva on duplex was 9% but rarely was associated with recurrences. The most common cause of recurrence was incompetent perforators and ovarian vein incompetence filling varices of the pudendal veins.

**Conclusion.** This non-randomised study included more severely affected limbs in the PIN stripping limbs, favouring a better outcome in the EVS group. In those patients at an early stage of the disease process where venous valve structure is essentially intact, EVS is a physiological alternative to PIN stripping in the treatment of varicose veins.

© 2007 European Society for Vascular Surgery. Published by Elsevier Ltd. All rights reserved.

**Keywords:** Recurrent varicose veins; External valvular stenting; Surgical treatment; Duplex ultrasonography.

### Introduction

The structural degradation of the venous valve is central to the understanding of the pathogenesis of varicose veins. Cotton<sup>1</sup> demonstrated the macroscopic and microscopic degradation of venous valves in patients with varicose veins. In the early stages, the cusps are unaffected with dilation of the valve ring being more important. As disease advances, the cusps become increasingly fibrotic, immobile and eventually fragmented and resorbed. Using intraoperative angiography, Yamaki<sup>2</sup> was able to correlate the macroscopic findings with pre-operative ultrasonic findings. The conclusions of this study indicated that minimal

cuspid degradation was associated with saphenofemoral junction (SFJ) internal diameters (ID) of less than 0.9 cm and a low peak reflux velocities of less than 30 cm/second.

Current treatment alternatives include ligation of the SFJ with perforate invaginate (PIN) stripping of the great saphenous vein (GSV), ultrasound guided sclerotherapy (UGS), radio frequency and endovenous laser ablation. These treatments obliterate the saphenous trunk, but also prevent the normal antegrade flow of blood. Surgical treatment in particular may lead to the development of new abnormal veins (vascular neogenesis) which are avascular.

Repairing incompetent venous valves by external valvular stenting (EVS) offers a physiological approach to the treatment of venous disease.<sup>3</sup> Graiche has shown that competence at the SFJ following EVS can be reliably predicated with pre-operative duplex

\*Corresponding author. R. J. Lane, 141 Edinburgh Road, Castlecrag NSW 2068, Australia.  
E-mail address: [rodlane@vsim.com.au](mailto:rodlane@vsim.com.au)

ultrasound, and stenting has been shown to create long lasting competence in animals and humans.<sup>4–6</sup>

The aim of this communication is to identify the reasons for recurrence in patients with EVS of the SFJ in comparison with simultaneous contralateral PIN-stripping. A strategy for preventing as well as treating the recurrences related to EVS is proposed.

## Materials and Methods

### *Patients*

The data reported here comes from two studies of the outcome of EVS. In the first, a comparative study of PIN-stripping in one leg and simultaneous contralateral EVS at the SFJ was performed in patients with GSV incompetence. There were 41 male and 152 female patients (mean age of 45 S.D. 11 years). The second group of patients presented with recurrent clinical varicose veins following EVS of the SFJ (39 consecutive patients). These were drawn from a larger database of patients who had undergone unilateral or bilateral EVS as part of their normal clinical management. PIN-stripping had not been performed as a control in this cohort.

Patients were recruited from two very large vascular clinics, Vascular Specialists Investigations & Management (Sydney, New South Wales), a private medical practice and, the Vascular Outpatients Clinic of Royal North Shore Hospital (Sydney, New South Wales). A teaching hospital of the University of Sydney, The institutional review board of Royal North Shore Hospital had approved a previous study involving EVS that resulted in Therapeutic Goods Administration (TGA) approval. The European Union subsequently approved Certificate Europe Marking. This device is shown in Fig. 1a and b.

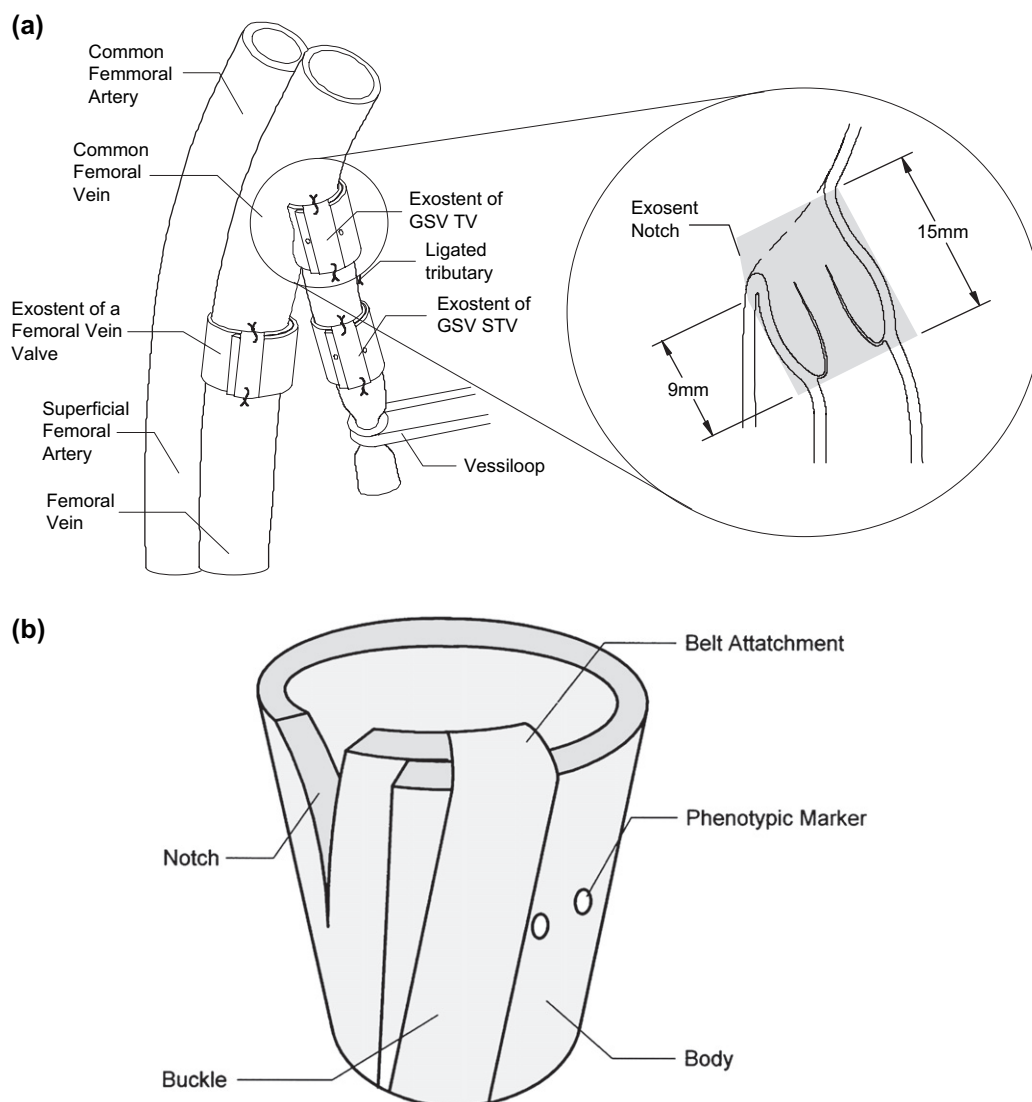
Patients included in this study underwent history taking and general physical examination including examination of the lower limbs to establish the extent of venous disease. History of previous episodes of venous thrombosis or a family history of thrombosis was sought. A history of previous venous surgery was also recorded. Many of the patients reported here were treated in the late 1980s, predating the introduction of the CEAP classification. In summary, retrospective application of the CEAP classification indicates that most patients were C<sub>2–4</sub>, A or S E<sub>P</sub> A<sub>S</sub> P<sub>R</sub>. Examination included assessment for suitability for anaesthesia as well as for peripheral arterial disease. Selection for EVS or PIN-stripping was determined by preoperative ultrasound findings.

### *Ultrasound assessment*

Duplex ultrasound was used to assess the anatomy and function of the deep and superficial veins in the lower limbs. A Logic 9 (General Electric, Milwaukee Wisconsin, USA) with 5–10 MHz and 6–13 MHz probes was used. The use of Brightness-flow (B-flow) to assess valve morphology was included in the imaging protocol for all patients. B-flow displays moving rouleaux of red blood cells and defines blood-flow characteristics including streaming and turbulence. Patients were examined while standing. The SFJ was assessed and competence of the terminal valve (TV) and sub-terminal valve (STV) were determined using a Valsalva manoeuvre, whilst manual calf compression-release was employed in the distal GSV. Scans were performed in longitudinal and transverse planes.

Patients included in this series had to have valves in which competence could be restored. On ultrasound examination, both valve cusps had to be visible and mobile. The remainder of the GSV was not excessively tortuous or dilated (>1 cm in women and >1.2 cm in men). Veins affected by acute or chronic thrombophlebitis were regarded as unsuitable. The diameters of the TV and STV and the inter-valve segments were recorded. The length of the valve leaflet was also measured and the appearance of the valve leaflets noted. The prediction of the final ID of the exostent required to create competence could be made by using these parameters. Brightness flow was used define the internal diameter (ID) of the stream of retrograde flow. For example, in Fig. 2 the valve ID is 8 mm and the reflux stream diameter is approximately 2 mm. Therefore, decreasing the aperture by 2–3 mm, i.e. a valve ID of 5 mm, should achieve competence. Fig. 3a is a B-mode image identifying the valve sinus and dilatation. Fig. 3b is a transverse section of a valve disruption using the same imaging modality. The management algorithm for EVS is demonstrated in Fig. 4.

The Venocuff II Surgical Pack (Allvascular, Sydney, New South Wales<sup>®</sup>) contains three exostents, two notched devices designated “L” and “R” for repairing the terminal valve (TV) at the left and right SFJ respectively, and an unnotched “D” (Fig. 1a and b). The unnotched exostent is used in deep venous valve reconstruction and when repairing the subterminal valve (STV) of the GSV. In the belt, three holes spaced at 3 mm intervals assist in determining the ID of the exostent required to create competence. When the belt is fed through the buckle, the appropriate hole is positioned in the centre of the buckle. The hole closest to the buckle is suitable for the GSV of a small

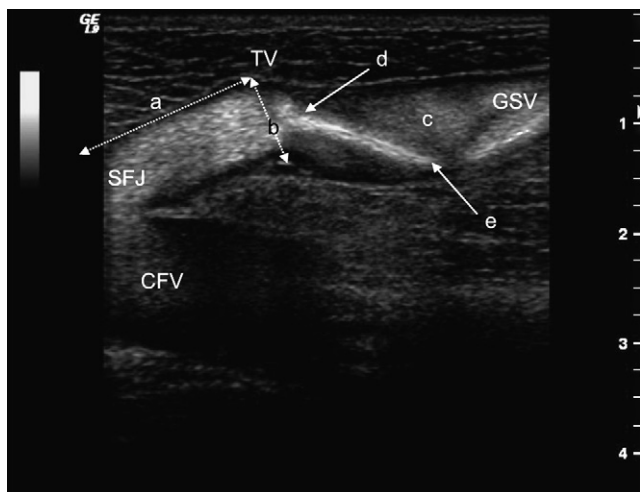


**Fig. 1.** (a) Schematic representation of a notched exostent positioned around the TV. An unnotched exostent is seen encircling the STV and a valve in the femoral vein. (b) Schematic representation of notched exostent for repairing the TV. This diagram also demonstrates the ability to create a conical shape which improves contact.

woman, i.e. exostent ID of 5.5 mm, resulting in a GSV diameter of 4.5 mm. The next hole on the belt indicates an exostent ID of 6.5 mm and GSV diameter of 5.5 mm. The third hole, i.e. exostent ID 7.5 mm and GSV diameter of 6.5 mm, is most commonly suitable for a large male when wall thickness is considered.

The position of the SFJ was marked pre-operatively by ultrasound imaging and prior to induction of anaesthesia 5,000 units of unfractionated heparin were given subcutaneously and 2,000 units intravenously. An antibiotic (usually a cephalosporin) was given intravenously. A skin crease groin incision was used and a standard approach made to the SFJ. The tributaries at the SFJ were clipped for access with maximal preservation. The common femoral vein

was exposed and the exact site of the TV and/or STV identified. The valve attachments can usually be seen through the adventitia of the vein. With a right-angle forceps, the exostent was introduced around the TV and the end of the exostent inserted into the buckle and tightened. By considering the length of the cusps, the ID of the SFJ preoperatively and the sex and bodily habitus of the patient, it was usually possible to predict the ID required to achieve competence. Papaverine was instilled locally to minimise vascular spasm. The valve was then tested by elevating the head of the bed in order to increase venous pressure. For patients under general anaesthesia, the anaesthetist was asked to assist in performing operative Valsalva. Where local anaesthetic was used,

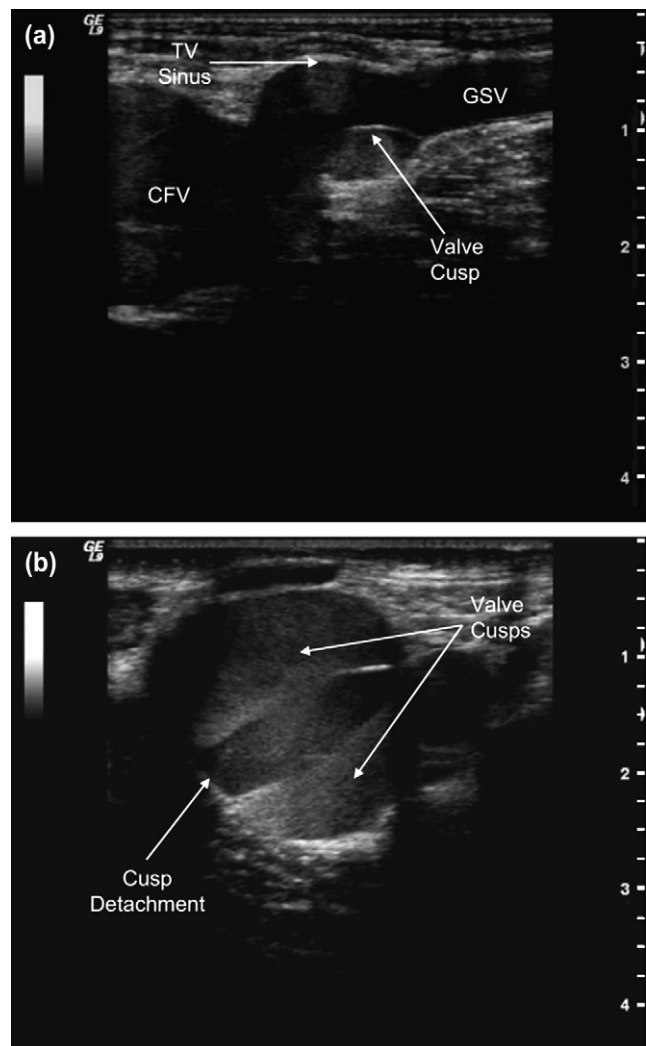


**Fig. 2.** B-flow image of the saphenofemoral junction and the terminal segment of the great saphenous vein (GSV). Several key points are displayed including (a), the position of the terminal valve (TV) in relation to confluence of the common femoral vein and GSV. The diameter of the TV (b), asymmetrical infravalvular sinus dilation (c), the reflux orifice (d) and (e), the reflux stream. CFV = common femoral vein; GSV = great saphenous vein; SFJ = saphenofemoral junction; TV = terminal valve.

the patient performed the Valsalva manoeuvre. If no reflux was seen, the diameter of the exostent was fixed using a 5.0 suture through the buckle, the belt, and the vein wall. Commonly, two sutures were required. A further suture was also used distally in order to maintain the diameter of the lower border of the exostent. Restricted access associated with a low ST valve may require suture fixation of the distal end of the stent initially. The stent was then slid distally to the level of the valve: proximal suture fixation encompasses the vein wall, the belt and buckle of the stent. If there was a residual reflux, the diameter was decreased. Competence was assessed by leaving an untied tributary below the valve repair following which the inflow was then occluded using a Vessiloop™ with maximal proximal venous pressure; there should be no bleeding through the untied tributary. The “Strip-Test” was an alternative where the inflow was blocked, following which a segment of the GSV between the Vessiloop™ and exostent was “milked” free of blood. If the valve was competent, the segment should remain empty. An endoscopic view of a valve following EVS is shown in Fig. 5.

A standard perforate invaginate (PIN) stripping procedure was performed in all patients where the GSV was deemed unsuitable for EVS.

Patients were reviewed at 1, 3 and 7 days post-operatively and again at 3 months. This was attended by the Vascular Surgeon who had performed the procedure or the Vascular Registrar if the patient was



**Fig. 3.** (a) B-mode image of the SFJ demonstrating symmetrical dilatation of the TV sinus and the presence of two normal cusps. CFV = common femoral vein; TV = terminal valve; GSV = great saphenous vein. (b) Transverse B-mode image of the TV of the SFJ. There appears to be some cusp detachment and the valve was deemed unsuitable for EVS.

operated on in the public hospital. Duplex ultrasonography was performed at 3 months. In the long term, patients were asked to return if they became symptomatic or developed varicose veins. No scheduled follow-up after 3 months was undertaken routinely. The recurrence criterion was strictly clinical, i.e. visible varicose veins >3 mm however a further ultrasound was always performed on all patients who returned with recurrent symptoms or veins. The ultrasound criterion for valvular incompetence was retrograde flow as determined by any of the modalities available, i.e. standard Pulsed Doppler spectral analysis, Colour Doppler, Power Doppler or B-flow.

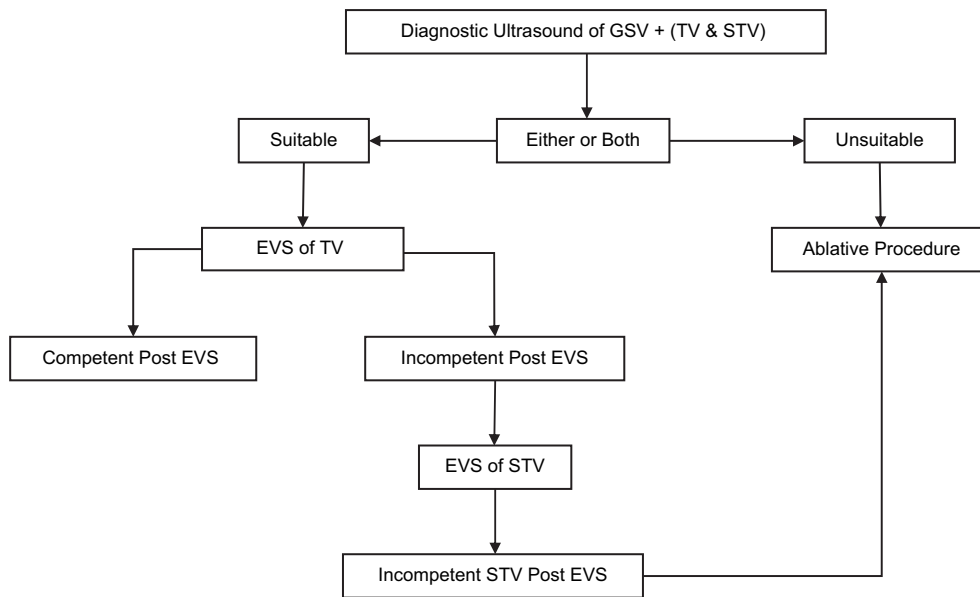


Fig. 4. Exostent Management Algorithm.

#### Statistical analysis

Independent data analyses were performed by Data-pharm (Australia). The Chi squared test was used to analyse contingency tables.

#### Results

The recurrence rate for all limbs was 12.4%. Fig. 6 illustrates the recurrence distribution in 386 limbs

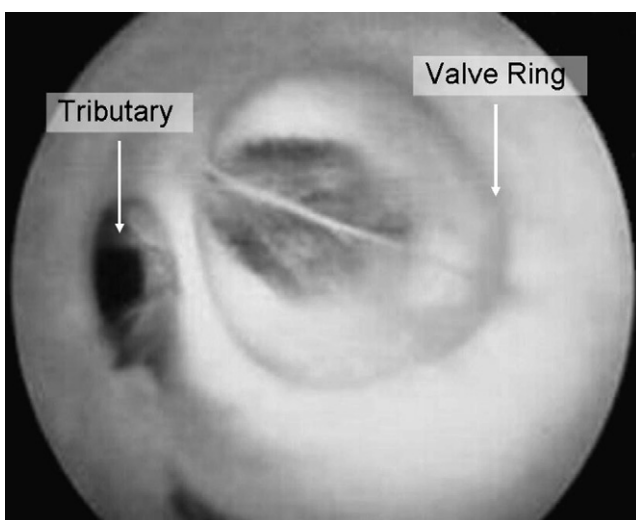


Fig. 5. Angioscopic view of a valve following successful EVS. The circular exostent can be inferred while a patent and incompetent tributary is also evident.

(193 patients). Recurrences rates at 68.5 months on the PIN-stripping side were 39/193 (20.2%). The contralateral simultaneous limbs with EVS were 9/193 or 4.6% (Chi square = 21.41,  $p < .001$ , 95% CI = 1.49 to 2.13). Residual reflux was present in 17/193, (9%) of the EVS repaired limbs as assessed at the 3 month post-operative duplex examination.

Table 1 shows the probable aetiology of 39 recurrences in patients in whom unilateral or bilateral EVS procedures were performed. In approximately 50% of limbs with recurrences, the SFJ was competent. Incompetent perforators, small saphenous veins recurrences, tributary incompetence or ovarian vein incompetence were often the source of the recurrence and were treated on their own merits during follow-up, often with ultrasound guided sclerotherapy. Numerically the most common recurrence appeared to be associated with reflux within the left ovarian vein and was usually associated with pregnancy. The pelvic veins filled varices in the lower limb through incompetent pudendal veins. Surgical treatment of the SFJ was not required in these cases many of which were managed by a combination of ovarian vein embolisation and UGS to the recurrent limb veins.

#### Discussion

The authors acknowledge that this was not a randomised study with patients and limbs being selected for EVS and the remainder of limbs being treated by

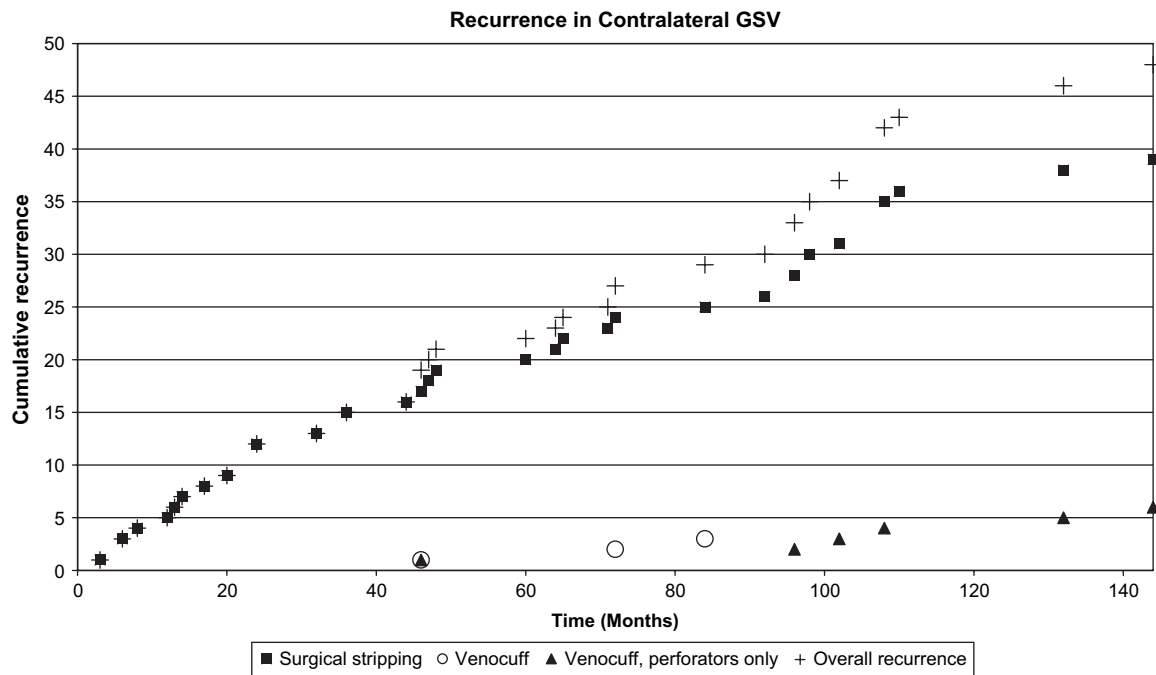


Fig. 6. Distributions of recurrence rates in the contralateral GSV.

PIN stripping. In order that EVS may be carried out, both cusps should be visible, and move with the respiratory cycle. They should not be thickened or distorted. The GSV itself should not be tortuous or dilated. This probably reflects an earlier stage in the disease process. EVS was carried out in young patients, 22% of whom were under the age of 35 years. Increasing public awareness of new methods of treating varicose veins probably encouraged a younger group of patients to attend our clinics for investigation. In this series, older patients were often relegated to PIN-stripping as they had a more advanced disease process. In summary, the limbs treated by PIN-stripping tended to be more severely affected than those undergoing EVS.

The recurrence rate of 20.2% after 12 years (68.5 months) of the PIN-stripping procedure is similar to that described by others.<sup>7-9</sup> The authors acknowledge

that only self-reported recurrence was assessed and no systematic search was made amongst all patients by routine assessment following the 3 month post-operative clinic attendance. Some clustering of recurrences in the initial phase probably represents missed initial sub-clinical varicose veins rather than new veins. As the EVS limb was often treated for less severe disease, the efficacy of this procedure may have been overestimated. The obvious solution to this problem would be to conduct a randomised study. This approach was attempted, however many patients withdrew themselves from the PIN-stripping cohort in favour of the EVS<sup>10</sup> resulting in an uneven distribution and confounding of the study. In some presentations, the TV was incompetent and associated with an incompetent lateral accessory saphenous system. The distal GSV was often normal. These factors perhaps exaggerate the low recurrence rate of 4.6% in the EVS cohort.

In general the distribution of recurrences comparing side to side was very different. Often the EVS side presented with GSV tributary incompetence very similar to a primary presentation of varicose veins. In contrast, the PIN-stripping sides were much more haphazard often associated with reticular veins, telangiectasia and neovascularisation. These differences may be due to preservation of the patency of the saphenous trunk in the EVS group. However, neovascularisation and development of telangiectases

Table 1. Aetiology of recurrences in patients following unilateral or bilateral EVS procedures

Aetiology	Number
Perforators, LSV, Tributaries, Short Saphenous	18
Stent Misplacement	5
Thrombophlebitis	3
New Reflux	10
Progressive Reflux	3
Total	39

are well known sequelae of saphenous stripping performed by any method.

Ascending incompetence was often associated with deep venous incompetence and/or obstruction and was a common cause of failure in both groups. In patients with early recurrences, i.e. less than five years, the exostent device may have been placed above or below the valve ring associated with abnormal valve ring location in relation to the confluence of the GSV with the CFV (Fig. 1). Inadequate preoperative ultrasonic valve selection was another cause of early recurrence. These reflect poorly on the accuracy of intraoperative testing systems for quality control purposes. Part of the problem relates to intra-operative spasm of the GSV. The exostent is positioned loosely and yet there is no reflux on testing. After the spasm wears off the valve ring dilates and reflux returns. Intra-operative papaverine is helpful in reducing spasm but does not appear to completely remedy the problem. Thrombophlebitis of the proximal end of the GSV is another cause of recurrence with stenting, usually in the mid-term, i.e. >5 years. The aetiology possibly relates to surgical trauma and ligation of tributaries for valve access, resulting in low flow at the SFJ. To minimise the incidence of postoperative thrombophlebitis, all patients were given papaverine intraoperatively and postoperative prophylactic subcutaneous heparin. Low dose aspirin was prescribed for the two weeks following surgery. The postoperative ultrasonic findings within the distal end of the GSV are often confused with thrombophlebitis. As the ID may change from 10 mm to 5 mm ID via external constriction the vein walls are often irregular and thickened having a "concertina" appearance, i.e. they mimic the ultrasonic findings of thrombophlebitis.<sup>10</sup>

There is considerable clinical discrepancy between residual reflux at the SFJ following EVS and long-term results. 9% of patients had residual SFJ reflux at post-operative assessment, but recurrent varices and symptoms were rare. More importantly there appears to be no progressive dilatation of the GSV. Even with reflux at the SFJ, the GSV reverts to normal size.<sup>5</sup> It appears that minor reflux may not be clinically significant considering that exostents are immutable in diameter and the valve ring can never dilate past an ID of 5 mm. Ultrasound with Valsalva is not physiological and exaggerates the pressure gradients across the SFJ valve. Therefore, the fact that following some EVS procedures reflux at the SFJ is reduced rather than completely abolished may be more appropriate. Residual reflux does not mean procedure failure. Kim has shown 80% complete competence post operatively following stenting of the SFJ but no follow up to indicate the progression of residual reflux was

recorded.<sup>11</sup> Greir and his colleagues documented similar findings with a five-year competence rate of 89% and a re-intervention rate of 5.7%.<sup>12</sup> A further group of EVS failures were patients who usually present many years later with new reflux in the GSV. In this group, ultrasound demonstrated competence of the repaired valve at 3 months following which reflux developed at some later stage without clinical or ultrasound evidence of thrombophlebitis. The aetiology of this long-term EVS failure remains unclear. Finally, patients presenting again with late onset of recurrence, more commonly women, had reflux in the GSV below competent proximal valves. In these patients there were significant varices bypassing the valve communicating with the GSV either between the TV and STV or below STV. These most often communicated with the tributaries of the superficial epigastric vein.

Minor recurrent varices may be managed by UGS but stripping of incompetent saphenous trunks can be readily achieved. In four limbs the STV has subsequently been successfully repaired, and in four cases PIN-stripping of the main trunk of the GSV below the exostent was employed with the distal end of the exostent oversewn. The exostent was left in situ to prevent CFV reconnection via neovascularisation: the concept is similar to that suggested by Glass<sup>13</sup> who implanted a mesh to minimise recurrence. There has been no evidence of clinically or ultrasonically detected groin neovascularisation in these patients. Endovenous laser ablation of the GSV has been performed in two limbs, which restored SFJ competence. The single most important principle regarding management of recurrence following EVS is that the treatment is much easier than coping with multiple neovascular recurrences and difficult groin resections which may be required to treat recurrence surgically following PIN-stripping procedures.

### Problems Related to the EVS Technique

Although EVS is very simple, careful surgical technique is paramount. The fundamental principles are careful identification of the valve, minimisation of surgical trauma, minimal surgically induced spasm, and preservation of as many competent tributaries as practical for adequate access. The greatest hurdle to producing long term results is patient selection. Surgeons are dependent upon ultrasound assessment which is notoriously operator dependent. The management of residual reflux needs clinical review. If the postoperative ultrasound evaluation shows residual reflux despite ablation of symptoms and return of

**Table 2. Summary of the literature of various authors performing EVS. STP: superficial thrombophlebitis**

Author (months)	<i>n</i>	Competency	Follow-up	STP	Infection rate	Other complications/Safety (tolerability)
Incandela <sup>13</sup>	16	100%	12	0.0%	0.0%	No complications
Zamboni <sup>14</sup>	35	93%	48	3.0%	0.0%	1 (3%) GSV thrombophlebitis that required stripping
Lane <sup>5</sup>	1516	90%	57	1.2%	0.3%	Thrombophlebitis requiring further treatment (0.3%) and requiring no treatment (0.7%).
Belcaro <sup>15</sup>	40	100%	93	0.0%	0.0%	No other problems associated with the device
Schanzer <sup>16</sup>	15	93%	10	–	0.0%	No complications
Zamboni <sup>17</sup>	64	94%	52	3.0%	0.0%	2 (3%) saphenous thrombophlebitis due to technical errors associated with hand sewing.
Corcos <sup>18</sup>	57	92%	12	4.0%	0.0%	There were 3 (5%) minor complications (2 pain and 1 lymphoedema) associated with the surgery.
Total/Average	1743	91%	37	2.0%	0.2%	

the GSV to normal size with reversal of tortuosity, intervention is not required. Residual reflux does not mean long term failure. Despite these issues, the concept of GSV preservation is well supported by other authors.<sup>18</sup> Table 2 is a summary of the literature of various authors performing EVS.

### Conclusion

External valvular stenting provides a more physiological solution to the management of early superficial venous disease affecting the GSV. The SFJ and saphenous trunk are preserved in contrast to PIN stripping. The latter may give rise to neovascularisation as well as to nerve damage.

However, in the series of patients with one limb treated by EVS and one treated by PIN stripping, the more severely affected limb was usually treated by PIN stripping. A further limitation of this investigation is that only self-reported recurrence was assessed. No systematic follow-up was performed after 3 months.

EVS is a simple surgical technique which is cost effective and can be performed under local anaesthetic as a day procedure with a short patient convalescence.

### Declaration in Regards to Funding and Conflicts of Interest

- Department of State and Regional Development Grant (New South Wales Government)
- Research & Development Grant (Australian Federal Government)
- Sponsorship by Droneon Pty Ltd
- Sponsorship by Imthage Pty Ltd

- Sponsorship by VasoProducts Pty Ltd
- Sponsorship by Bellara Medical Pty Ltd.
- Dr Mark Phillips is funded by the Department of Vascular Surgery, Royal North Shore Hospital and Allvascular Pty Ltd.
- Dr Rodney James Lane is on the board of Directors of Allvascular Pty Ltd.

### References

- 1 COTTON LT. Varicose veins: gross anatomy and development. *Br J Surg* 1961;**48**:589–598.
- 2 YAMAKI T, SASAKI K, NOAZAKI M. Preoperative duplex-derived parameters and angioscopic evidence of valvular incompetence associated with superficial venous insufficiency. *J Endovasc Ther* 2002;**9**:229–233.
- 3 GRAICHE JA, LANE RJ, CUZZILLA ML, CORONEOS JC, BERNEY CR. Insuffisance valvulaire veineuse: imagerie par ultrasonographie et réparation par manchonnage. *Phlebologie* 2004;**3**:237–252.
- 4 LANE RJ. The correction of pathological venous valve with the "Venocuff". Doctor of medicine Thesis. University of Sydney 1992.
- 5 LANE RJ, CUZZILLA ML, CORONEOS JC. The treatment of varicose veins with external stenting to the sapheno-femoral junction. *Vasc Endovascular Surg* 2002;**36**:179–192.
- 6 LANE RJ, McMAHON C, CUZZILLA ML. Treatment of varicose veins using the venous valve cuff. *Phlebologie* 1994;**9**:136–145.
- 7 McADAM WAF, HORROCKS JC, DE DOMBAL FT. Assessment of the results of surgery for varicose veins. *Br J Surg* 1976;**63**:137–140.
- 8 LOFGREN EP, LOFGREN KA. Recurrence of varicose veins after the stripping operation. *Arch Surg* 1971;**102**:111–114.
- 9 NABATOFF RA. Reasons for major recurrence following operations for varicose veins. *Surg Gynecol Obstet* 1969;**128**:275–278.
- 10 LANE RJ, CUZZILLA ML. The indications to repair the saphenofemoral junction with external valvular stenting. *Aust J Phlebology* 2001;**5**:6–11.
- 11 IK KIM D, BOONG LB, BERGAN J. Venous haemodynamic changes after external banding with vascosectomy in the treatment of primary varicose veins. *J Cardiovasc Surg* 1999;**40**:567–570.
- 12 GEIER B, BARBERA L, STUCKER M, EL GAMMAL S, MUMME A. Venenerhaltende therapie der stamminsuffizienz der V saphena magna:



- erfahrungen mit der extraluminale valvuloplastie. *Vasomed* 2002;**14**:240–246.
- 13 INCANDELA L, BELCARO G, NICOLAIDES AN, ANUS G, ERRICHI BM, CESARONE MR *et al.* Superficial vein valve repair with a new valve support (EVS). The IMES (International Multicenter EVS Study). *Angiology* 2000;**51**(8 Pt 2):S39–S52.
- 14 ZAMBONI P, GASBARRO V, MARCELLINO MG, MURGIA AP, LIBONI A, DONIN I. External valvuloplasty of the saphenofemoral junction. *Vasc Surg* 1994;**28**(5):327–336.
- 15 BELCARO G, NICOLAIDES AN, ERRICHI BM, INCANDELA L, DE SANCTIS MT, LAURORA G *et al.* Expanded polytetrafluoroethylene in external valvuloplasty for superficial or deep vein incompetence. *Angiology* 2000;**51**(8 Pt 2):S27–S32.
- 16 SCHANZER H, SKLADANY M. Varicose vein surgery with preservation of the saphenous vein: a comparison between high ligation-avulsion versus saphenofemoral banding valvuloplasty-avulsion. *J Vasc Surg* 1994;**20**:684–687.
- 17 ZAMBONI P, MARCELLINO MG, CAPPELLI M, FEO CV, BRESADOLA V, VASQUEZ G *et al.* Saphenous vein sparing surgery: principles, techniques, and results. *J Cardiovasc Surg* 1998;**39**:151–162.
- 18 CRETON D. A nondraining saphenous system is a factor of poor prognosis for long-term results in surgery of great saphenous vein recurrences. *Dermatol Surg* 2004;**30**:744–749.

Accepted 26 June 2007

Available online 18 September 2007