



## An Expanded Series of Distal Bypass Using the Distal Vein Patch Technique to Improve Prosthetic Graft Performance in Critical Limb Ischemia<sup>☆</sup>

R.F. Neville<sup>a,\*</sup>, M. Lidsky<sup>b</sup>, A. Capone<sup>b</sup>, J. Babrowicz<sup>a</sup>, R. Rahbar<sup>a</sup>, A.N. Sidawy<sup>a</sup>

<sup>a</sup> Division of Vascular Surgery, Department of Surgery, MFA at George Washington University, 2150 Pennsylvania Avenue, 6B-407, Washington, DC 20037, USA

<sup>b</sup> Georgetown University School of Medicine, 3900 Reservoir Road Northwest, Washington, DC 20007, US

### WHAT THIS PAPER ADDS

- This expanded series is a more accurate reflection of expected results confirming that the distal vein patch bypass leads to reasonable long-term results for those challenging patients that require prosthetic distal bypass for lower extremity revascularization. Vascular surgeons engaged in the treatment of patients with limb threatening ischemia may wish to add this technique to their options for lower extremity revascularization for limb salvage.

### ARTICLE INFO

#### Article history:

Received 1 January 2012

Accepted 16 April 2012

Available online 15 May 2012

#### Keyword:

Distal vein patch bypass

### ABSTRACT

**Objectives:** The endovascular first approach has led to increasing complexity for surgical bypass especially in those patients without autogenous conduit. The use of vein interposed at the distal anastomosis has been reported to improve the results of prosthetic grafts. This series expands our initial experience with the distal vein patch technique (DVP) reporting a larger cohort with enhanced follow-up.

**Design:** A retrospective review of prospectively collected data was performed for distal bypasses from July 1995 to November 2008.

**Materials/Methods:** 1296 tibial bypasses were performed with 270 using the DVP technique. Patient demographics included; 49% diabetes, 20% chronic renal failure, 33% prior failed bypass. Indications for revascularization were claudication (9.3%), rest pain (27.8%), gangrene (22.2%), and non-healing ulceration (40.7%). Lack of vein for the bypass conduit resulted from previous failed grafts (55%), coronary bypass (18%), poor quality vein (23%), or prior vein stripping (8%). Follow-up ranged from 1 to 48 months with graft surveillance by pulse exam, ABI, and Duplex ultrasound. Primary patency and limb salvage  $\pm$  SE were determined by Kaplan–Meier life-table analysis using Rutherford criteria.

**Results:** Bypasses originated from the external iliac (29%), CFA (55%), SFA (13%), popliteal (1%), and prior grafts (2%). Recipient arteries were below knee popliteal (6%), anterior tibial (25%), posterior tibial (30%), and peroneal (39%). Perioperative graft failure occurred in 13 cases with a total of 41 graft failures leading to 39 major amputations. Primary graft patency from one to four years was 79.8%, 75.6%, 65.9%, and 51.2%. Corresponding limb salvage rates were 80.6%, 78.0%, 75.7%, and 67.5%.

**Conclusion:** Although not addressed by a randomized trial, we believe this expanded series is a more accurate reflection of expected results confirming that the DVP bypass leads to reasonable long-term results for those challenging patients that require prosthetic distal bypass for lower extremity revascularization.

© 2012 European Society for Vascular Surgery. Published by Elsevier Ltd. All rights reserved.

### Introduction

Despite the rapid development of endovascular therapy, bypass continues to play an important role in below knee revascularization

for limb threatening ischemia. An “endovascular first” approach has been adopted by many centers resulting in a decrease in the number of lower extremity bypasses performed from critical limb ischemia.<sup>1</sup> The only randomized trial to compare angioplasty and bypass is the BASIL trial (Bypass versus Angioplasty in Severe Ischemia of the Leg).<sup>2</sup> This comparison suggested that bypass may be the preferred method of revascularization in patients with more than a two year life expectancy and the presence of good quality

<sup>☆</sup> Presented at the Society for Clinical Vascular Surgery, 36th Annual Scientific Meeting.

\* Corresponding author. Tel.: +1 11 202 741 3210.

E-mail address: [rneville@mfa.gwu.edu](mailto:rneville@mfa.gwu.edu) (R.F. Neville).

saphenous vein for the conduit. Although vein has been shown to provide the best patency and remains the preferred conduit, adequate autogenous tissue may not be available leaving a prosthetic graft an option for certain patients.<sup>3,4</sup> This group has been estimated at 30% of those needing distal reconstruction with an increase to 50% for those undergoing a repeat or secondary procedure.<sup>5</sup> Unfortunately, reported patency for below knee bypass with a prosthetic graft ranges between 20% and 50% at one year and 12%–40% at three years.<sup>3,6–8</sup>

Attempts to improve the performance of prosthetic grafts have included the interposition of venous tissue at the distal anastomosis in the form of cuffs, collars, and boots. The distal vein patch technique was initially developed to enhance the performance of polytetrafluoroethylene (PTFE) bypasses while taking advantage of anastomotic techniques familiar to vascular surgeons.<sup>9</sup> Our initial experience with this technique was reported in 2001 for a relatively small patient cohort with limited follow-up.<sup>10</sup> The current series examines the results of a larger and more mature patient population requiring below knee bypass using PTFE with a distal vein patch (DVP).

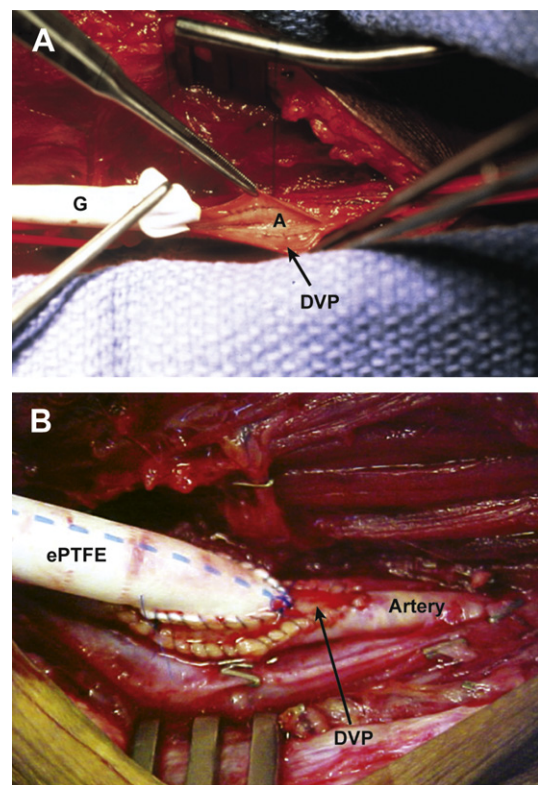
## Materials and Methods

A retrospective review of prospectively collected data was performed (with IRB approval, No. 2008-091) for all below knee bypasses using the distal vein patch (DVP) technique from July 1995 to November 2008. During the review period, 270 infrapopliteal prosthetic bypass grafts were performed in 252 patients using the DVP technique. During this time period there were a total of 1296 infrapopliteal bypasses performed so that the DVP group represented 20.8% of the below knee bypass experience. All prosthetic grafts used were expanded polytetrafluoroethylene (ePTFE) with external, removable rings (WL Gore<sup>R</sup>, Flagstaff, AZ). Arteriography was performed in all patients for preoperative planning of the bypass. Prior to the decision to use PTFE with a DVP, efforts were expended to find autogenous venous tissue suitable to use as a bypass conduit. Physical examination supplemented with Duplex ultrasonography was conducted to locate ipsilateral or contralateral saphenous vein. If vein of adequate length but questionable quality was identified, then evaluation under direct vision was performed intraoperatively with gentle hydrostatic dilation. The use of prosthetic graft material occurred due to a lack of autogenous vein for the following reasons; coronary artery bypass (18%), prior lower extremity bypass (55%), venous stripping (8%), or poor vein quality of insufficient length or diameter (23%).

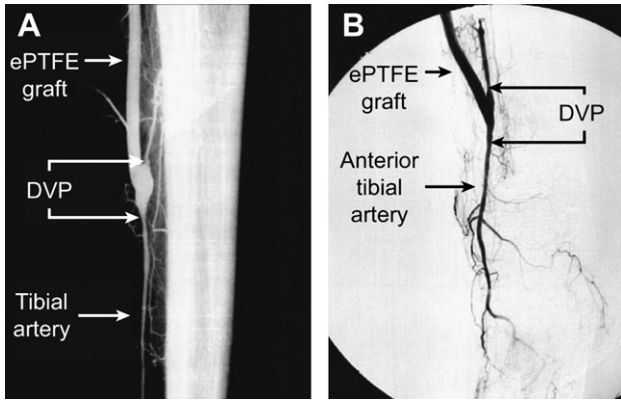
Bypass procedures were performed under general or epidural anesthesia based on the patient's medical condition and the judgment of the attending anesthesiologist. A retroperitoneal approach to the external iliac artery was used in several cases to avoid groin scarring due to previous femoral artery dissection from prior bypass procedures. This incision was made several centimeters above and parallel to the inguinal ligament with dissection through the external oblique fascia and transection of the internal oblique and transversalis muscle fibers to enter the retroperitoneal space. Distal arterial exposure varied according to the artery chosen for the outflow anastomosis. An externally reinforced, 6-mm, thin-walled PTFE graft was then tunneled between the proximal and distal arterial dissections. The graft tunnel was routed medially when possible; however, when a bypass graft to the proximal anterior tibial artery was planned, the tunnel was made laterally. A lateral tunnel was also used in cases where the distal peroneal artery was targeted via a lateral approach with segmental fibulectomy. Also taken into consideration for graft tunneling was avoidance of excessive scar formation or open wounds. After systemic heparinization, the proximal anastomosis was performed using an end-to-

side anastomosis between the PTFE graft and the inflow artery with a standard “parachute” suturing technique. A DVP was performed at the distal anastomosis of each bypass as previously described.<sup>8</sup> A 2–4 cm segment of autogenous tissue was harvested including saphenous vein remnants, basilic vein, cephalic vein, and rarely superficial femoral vein. The tissue segment was gently irrigated with prepared vein solution (Plasma-Lyte-A: 1000 mL, pH 7.4, heparin 5000 units, calcium chloride 10%, 100 mg, and papaverine 120 mg) and opened longitudinally with any venous valves directly excised. The distal arteriotomy was performed and the vein segment sutured to the artery as a patch with 7-0 Prolene by means of standard “parachute” techniques. A longitudinal venotomy was then made in the proximal two thirds of the patch in order to locate the prosthetic anastomosis near the heel of artery-patch suture line but leaving the distal one third of the venous anastomosis free of any PTFE. The PTFE graft was then sutured to the vein patch with 6-0 Prolene. (Fig. 1A) The vein patch provides an autogenous interface between the artery and the prosthetic graft, but does not “balloon out” in a hemodynamically disadvantageous configuration.<sup>11</sup> (Fig. 1B) Completion arteriograms were obtained routinely early in the series, but are currently obtained selectively based on intraoperative ultrasound findings. (Fig. 2A and B).

The post operative protocol included the use of aspirin and warfarin to maximize graft function given that 6 mm ePTFE was the conduit.<sup>12,13</sup> Over 90% of patients were on aspirin preoperatively, and the remaining were started on aspirin post bypass if they had no contraindication to antiplatelet therapy. A heparin infusion was started 2–4 h postoperatively to assure operative hemostasis and continued for 48 h with conversion to oral warfarin therapy in those patients without a contraindication to long-term anticoagulation with an international normalized ratio between 1.8 and



**Figure 1.** Intraoperative view of the DVP anastomosis with prosthetic, vein patch and artery. A. ePTFE being sutured to the venotomy in the vein patch. B. Completed anastomosis.



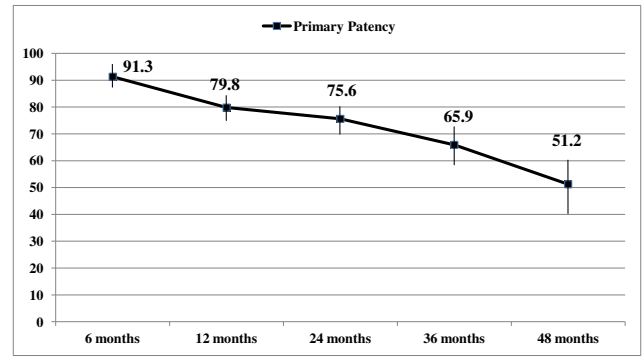
**Figure 2.** Completion arteriograms after DVP bypass. A. Arteriogram after DVP bypass to the distal posterior tibial artery. B. Arteriogram after DVP bypass to the distal anterior tibial artery.

of 3.0 as the goal. Patients were seen in the office 7–10 days after discharge from the hospital. The follow-up protocol included pulse examination and Duplex ultrasound surveillance at 3 months, 6 months, and annually. If Duplex ultrasound revealed anastomotic stenosis (increased velocities) or threatened flow (decreased mid graft velocity) then an arteriogram was performed to assess the ability to extend graft function with an intervention. If a graft was thrombosed at follow-up by Duplex ultrasound or pulse exam, the patient was taken to the operating room for graft thrombectomy and revision if feasible.

**Results**

Two hundred and seventy grafts were performed in two fifty four patients. The patient cohort was comprised of 54% males and 46% females with a mean age of  $70.5 \pm 11.1$  years. Racial demographics were 53.3% Caucasian, 43% Black, and 3.7% Hispanic and Oriental. Comorbid conditions included diabetes mellitus (49.6%), chronic renal failure on dialysis (20.6%), and medically treated hypertension (68.2%). Indications for revascularization were claudication (9.3%), rest pain (27.8%), gangrene (22.2%), and non-healing ulceration (40.7%) with 62.9% of patients presenting with tissue loss. Prior revascularization had been attempted in 33.3%. Bypass grafts originated from the external iliac artery in 29%, the common femoral artery in 55%, the superficial femoral artery in 13%, the popliteal artery in 1%, and another graft limb in 2%. The recipient arteries included the below knee popliteal in 6%, anterior tibial artery in 25%, the posterior tibial artery in 30%, and the peroneal artery in 39% procedures with tibial artery bypass comprising 94% of the bypass cohort.

Graft patency and limb salvage rates were determined at follow-up intervals ranging from 1 month to four years. There was one (0.5%) perioperative death due to a myocardial infarction, with a 12.6% total mortality rate during the four-year follow-up period. Perioperative graft failure occurred within thirty days of surgery in thirteen cases. There were an additional twenty eight failures beyond this thirty day perioperative period for a total of 41 known graft failures in the series. This led to 39 major amputations performed above the ankle (BKA, AKA). Data were evaluated using standard Kaplan Meyer life-table analysis and reported as primary patency and limb salvage  $\pm$  SE.<sup>5</sup> Primary graft patency was  $91.3 \pm 2.0\%$  at 6 months,  $79.8 \pm 3.4\%$  at 12 months,  $75.6 \pm 4.4\%$  at 24 months,  $65.9 \pm 6.1\%$ , at 36 months, and  $51.2 \pm 8.4\%$  at 48 months. (Fig. 3) Limb salvage rates were  $90.7 \pm 2.1\%$  at 6 months,  $80.6 \pm 3.4\%$  at 12 months,  $78.0 \pm 4.2\%$  at 24 months,  $75.7 \pm 5.6\%$  at 36 months, and  $67.5 \pm 8.0\%$  at 48 months. (Fig. 4).

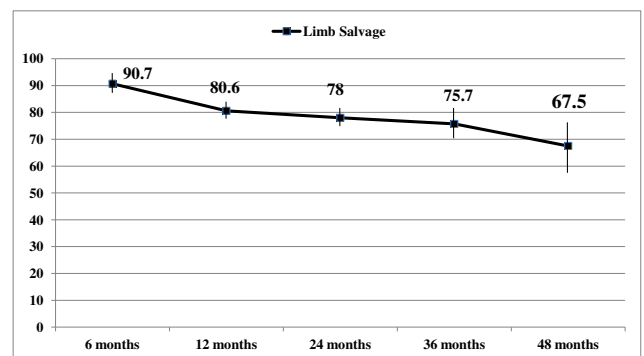


**Figure 3.** Graph of primary patency with corresponding life-table.

Further analysis of the failed grafts included risk factor assessment, as well as inflow and outflow graft anatomy. Twenty of the graft failures (49%) occurred in diabetic patients who accounted for 57% of the patient series. Nine of the graft failures (22%) occurred in the renal failure group which was 25% of the total series. This indicated no disproportionate failure rates for diabetic or renal failure patients. Inflow anatomy of the failed grafts showed that five occluded grafts originated from the limb of a prior aorto-femoral bypass graft representing 100% failure in this group.

**Discussion**

Several anastomotic modifications have been proposed to improve prosthetic graft performance in patients requiring below knee bypass. Our initial experience with the DVP technique reported only 19 patients beyond two years of follow-up. A larger patient cohort with longer follow-up intervals was deemed necessary to confirm the preliminary clinical findings. The current study involves a larger patient cohort at extended periods of time



**Figure 4.** Graph of limb salvage with corresponding life-table.

with 121 patients beyond two years and 46 patients at the 4-year follow-up interval. The primary patency rate at four years in this expanded series is lower than reported in the initial study; 51% vs. 62%. The larger sample size at longer follow-up intervals reveals a more accurate representation of DVP performance.

Venous tissue was first interposed between the prosthetic graft and a recipient artery in order to ease the technical difficulty of suturing the stiff graft to small, calcified arteries.<sup>14</sup> Miller reported on 114 infrainguinal procedures using a vein cuff technique with a patency rate of 72% noted at 18 months.<sup>15</sup> However, several disadvantages were recognized with this configuration including significant turbulence at the anastomotic reservoir and difficulty achieving a proper angle between the graft and recipient artery. These factors may explain the immediate and early graft failures reported in Miller's initial series. Taylor described a technique to address several of these concerns reporting on 256 grafts (83 tibial bypasses) with 1, 3, and 5-year patency rates of 74%, 58%, and 54%, respectively.<sup>16</sup> However, there are also disadvantages with this technique. The tibial artery is directly exposed to PTFE graft material for the proximal half of the anastomosis thereby losing the advantage of venous endothelium for half the anastomosis. There can also be a point of anastomotic constriction where the three suture lines converge between the artery, PTFE, and vein patch. Finally, a significant length of vein must be available to accomplish the anastomosis using the Taylor technique. The St Mary's boot technique has been advocated as taking advantage of the best features of the prior techniques with promising early clinical results. The corner of the vein is sutured to the apex of the arteriotomy to form the anastomotic toe. The remainder of the venous-arterial anastomosis is formed in a similar fashion to the Miller cuff, however the redundant vein is excised obliquely and sutured to the longitudinal edge. A segment of the posterior collar is incised to increase the size of the anastomosis between the graft and vein collar. The St Mary's boot maintains a fully compliant venous collar, avoids any direct contact between artery and PTFE, and maintains the hemodynamic advantages of the Taylor patch. Its main drawback is the increased suturing technical complexity.<sup>17</sup> Technique is critical for the successful construction of the Miller

cuff, Taylor patch, and St. Mary's boot. The DVP technique was developed in response to this apparent complexity and theoretical disadvantages. We combined a standard patch angioplasty technique familiar to vascular surgeons with subsequent implantation of the PTFE graft into the patch.

Several authors have reported their results with these techniques. (Table 1) Kansal and colleagues obtained improved patency for prosthetic bypasses with the Miller cuff when as compared to historical controls with straight PTFE.<sup>18</sup> A prospective, randomized trial utilizing PTFE grafts with and without a Miller vein cuff was reported by Stonebridge. This series did not demonstrate a statistically significant benefit for the vein cuff technique in tibial bypasses, although there was a trend toward improved patency at 24 months.<sup>19</sup> Kreienberg compared grafts using PTFE with a vein cuff versus composite saphenous vein grafts. Primary patency was similar at two years; 49% cuff vs. 44% composite vein with secondary patency rates somewhat better for the composite vein group.<sup>20</sup> The Albany group compared all bypasses with spliced vein segments to PTFE and a Miller vein cuff.<sup>21</sup> The patency was better with the vein bypasses although 25% of the spliced vein procedures required revision to obtain these results. Additionally, spliced vein procedures involved increased operative time, hospital stay, intra-operative blood loss, and perioperative morbidity. Therefore, composite grafts of poor quality vein do not function any better than PTFE with a vein cuff or patch and generate a higher rate of morbidity and use of hospital resources. Our results have been supported by European studies using the same technique. Flis found improved primary patency and limb salvage using the DVP bypass as compared to PTFE alone.<sup>22</sup> Bellosta compared the DVP, the vein cuff, and pre-cuffed PTFE and demonstrated that the DVP provided better results than the other two distal anastomotic configurations.<sup>23</sup>

The reasons for suboptimal performance with prosthetic grafts especially below the knee are technical, biological, and hemodynamic. Technically, the anastomosis involves suturing a prosthetic graft material to small, often calcified tibial arteries. Biologically, PTFE grafts are more thrombogenic than autogenous conduits with increased platelet adhesion and activation of the coagulation

**Table 1**  
Comparative table including data gleaned from articles that reported results on specific data points with the Miller cuff, Taylor patch, St. Mary's boot, and Distal Vein Patch. Data may have been collected in the context of a trial involving other techniques, and only data that could be gleaned from the publication regarding vein interposition techniques were used. While not a statistical comparison, this is as near a comparison of like-kind data as possible.

Series	N	BK popliteal vs Tibial	1	2	3	4	5
<i>Miller Cuff</i>							
Miller, 1984 <sup>15</sup>	114			72 (18m)			
Raptis, 1995 <sup>27</sup>		BK popliteal 100%			57		
Stonebridge, 1997 <sup>19</sup>	96	BK popliteal 100%	80	52			
Kansal, 1999 <sup>18</sup>	56	BK popliteal 47% Tibial 53%	62	54	30		
Stonebridge, 2000 <sup>28</sup>	89	Tibial 100%	50	32			
Panneton, 2004 <sup>29</sup>	44	BK popliteal 21% Tibial 79%	62	44			
Griffiths, 2004 <sup>30</sup>		BK popliteal 100%				45	
Oderich, 2005 <sup>31</sup>		BK popliteal 35% Tibial 65%	78			54	
Lauterbach, 2005 <sup>32</sup>	105	BK popliteal 38% Tibial 62%	79	75		64	
<i>Taylor Patch</i>							
Taylor, 1992 <sup>16</sup>	86	BK popliteal	88		77		65
	83	Tibial	74		58		54
Yeung, 2001 <sup>33</sup>	44		71	71			
<i>St. Mary's Boot</i>							
Tyrell, 1991 <sup>17</sup>	30		40				
Kreienberg, 2000 <sup>20</sup>	59	BK popliteal 12% Tibial 88%		45	38		
Kreienberg, 2002 <sup>21</sup>	20	BK popliteal 20% Tibial 80%		49			
<i>DVP</i>							
Neville, 2001 <sup>10</sup>	80	Tibial 100%	82	77	69	62	
Flis, 2001 <sup>22</sup>	86	BK popliteal Tibial					53 vs 29
Bellosta, 2005 <sup>23</sup>	22	Tibial 100%				62 (secondary)	
Neville, 2012 (current)	270	BK popliteal 6% Tibial 94%	79	75	65	51	

cascade.<sup>24</sup> Increased thrombogenicity at the graft surface results in early graft thrombosis especially when blood flow falls below the critical thrombotic threshold. Late graft failure due to myointimal hyperplasia occurs six to twenty four months postoperatively usually at the distal anastomosis. This hyperplastic response is the result of smooth muscle cell migration and proliferation primarily at the toe and heel of the anastomosis causing a reduction in lumen area and subsequent graft failure. Although the causes of myointimal hyperplasia have not been completely delineated, viable venous tissue at the anastomosis may create a “biologic buffer zone” and alter the stimulation of factors responsible for the hyperplasia responsible for late failure with PTFE.<sup>25</sup> Venous endothelium may also confer a beneficial effect through antiplatelet and fibrinolytic activity, although these effects remain unproven. The hemodynamic factors of shear stress and compliance mismatch have also been implicated in prosthetic graft failure. Hypothetically, vein interposed between the prosthetic material and the more compliant artery would minimize the expansibility mismatch created with pulsatile flow and thus decrease mechanical injury at the anastomosis. However, an animal study addressing compliance did not prove compliance to be a significant contributory factor in the reduction of hyperplasia.<sup>26</sup> Anastomotic turbulence, shear forces and outflow resistance have also been suggested as mechanisms of graft failure. Anastomotic geometry may be altered by the presence of vein at the distal anastomosis, thereby effecting turbulence and shear forces that play a role in the hyperplastic process. We have used magnetic resonance velocimetry with three dimensional, time varying velocity measurements to analyze hemodynamics in differing anastomotic geometries.<sup>11</sup> Flow structures revealed marked hemodynamic differences between standard and cuffed anastomotic geometries. The findings supported an end-to-side anastomosis with a low incident angle as producing a favorable hemodynamic result as compared to a Miller pre-cuffed configuration. The DVP and Taylor anastomoses closely approximate the hemodynamic advantages of the conventional, straight anastomotic pattern. Finally, venous tissue may simply enlarge the distal anastomosis so that the formation of hyperplasia must encroach on a wider lumen to cause its occlusion making this response less critical when a patch is added to the distal anastomosis.

We developed the DVP to incorporate techniques familiar to vascular surgeons while maintaining the proposed advantages of vein interposition in improving outcomes for prosthetic grafts. The DVP involves a standard patch angioplasty technique familiar to vascular surgeons with implantation of a PTFE graft into the proximal portion of the vein patch. The length of autogenous tissue required for the patch is minimized compared to the Miller cuff and Taylor patch. Autogenous tissue is interposed between the graft and the recipient arterial wall for the entire anastomosis unlike the Taylor patch, and there is not the “bulging” noted with the Miller cuff. Diabetes and renal failure did not have a disproportionate incidence of graft failure, and remain candidates for DVP bypass if needed for limb salvage. The patency rate in the current series represents a more mature evaluation of the DVP technique with more robust long-term follow-up as compared to series reporting other vein interposition techniques.

There was an important observation from grafts that did fail. Graft thrombectomy and revision was simplified by this technique. Ordinarily, prosthetic grafts fail due to hyperplasia at the suture line between the graft and recipient artery resulting in thrombosis of the recipient artery. When the DVP bypasses failed, the recipient artery was rarely thrombosed because the hyperplastic response led to stenosis between the vein patch and ePTFE, leaving the native artery patent and available for revision. This allowed reestablishment of graft patency by thrombectomy with revision of the distal

anastomosis by extension of the patch across the hyperplastic area onto patent native artery.

In this era of endovascular therapy, lower extremity bypass will become increasingly challenging as catheter based therapies continue to evolve. Patients with extensive occlusive disease and significant tissue loss may be best treated with bypass. Accordingly, bypass will be used in this cohort for non-healing wounds or gangrene especially when direct, pulsatile perfusion is required for healing and maximal tissue salvage. This aggressive approach to limb salvage and wound healing will require bypass in patients without an adequate length of autogenous conduit. Our initial experience with the DVP was encouraging, but limited in terms of long-term follow-up. We believe the DVP anastomosis involves technical, biological, and hemodynamic factors that lead to the reported results. As compared to our initial report, this expanded series is an enhanced reflection of expected performance with the DVP bypass, and confirms that PTFE with a DVP leads to acceptable long-term patency and limb salvage in patients with critical ischemia in need of distal bypass and a lack of autogenous conduit.

### Conflict of Interest/Funding

None.

### References

- 1 Beard JD. Which is the best revascularization for critical limb ischemia: endovascular or open surgery? *J Vasc Surg* 2008;**48**: 11–16S.
- 2 Basil trial participants. Bypass versus angioplasty in severe ischemia of the leg; multicenter, randomized controlled trial. *Lancet* 2005;**366**:1925–34.
- 3 Hobson RW, Lynch TG, Jamil Z, Karanfilian R, Lee B, Padberg F, et al. Results of revascularization and amputation in severe lower extremity ischemia: a five-year clinical experience. *J Vasc Surg* 1985;**2**:174–85.
- 4 Bandyk DF, Kaebnick HW, Stewart SW, Towne JB. Durability of the in-situ saphenous vein arterial bypass: a comparison of primary and secondary patency. *J Vasc Surg* 1987;**5**:256–68.
- 5 Brewster DC. Composite grafts. In: Rutherford RB, editor. *Vascular surgery Philadelphia: WB Saunders* 1989. p. 481–6.
- 6 Dalsing MC, White JV, Yao JST. Infrapopliteal bypass for established gangrene of the forefoot or toes. *J Vasc Surg* 1985;**2**:669–77.
- 7 Bergan JJ, Veith FJ, Bernhard VM. Randomization of autogenous vein and polytetrafluoroethylene grafts in femorodistal reconstruction. *Surgery* 1982;**92**:921–30.
- 8 Whittemore AD, Craig KK, Donaldson MC, Couch N, Mannick JA. What is the proper role of polytetrafluoroethylene grafts in infrainguinal reconstruction? *J Vasc Surg* 1989;**10**:299–305.
- 9 Neville RF, Attinger C, Sidawy AN. Prosthetic bypass with a distal vein patch for limb salvage. *Am J Surg* 1997;**174**:173–6.
- 10 Neville RF, Tempesta B, Sidawy AN. Tibial bypass for limb salvage using polytetrafluoroethylene with a distal vein patch. *J Vasc Surg* 2001;**33**(2):266–72.
- 11 Neville RF, Elkins CJ, Alley MT, Wicker R. Hemodynamic comparison of differing anastomotic geometries using magnetic resonance velocimetry. *J Surg Res* 2010;**169**(2):311–8.
- 12 Johnson WC, Williford WO. Benefits, morbidity, and mortality associated with long-term administration of oral anticoagulant therapy to patients with peripheral arterial bypass procedures: a prospective randomized study. *J Vasc Surg* 2002;**35**:413–21.
- 13 Brumberg RS, Back M, Armstrong P, Cuthbertson D, Shames M, Johnson B, et al. The relative importance of graft surveillance and warfarin therapy in infrainguinal prosthetic bypass failure. *J Vasc Surg* 2007;**46**:1160–6.
- 14 Siegman FA. The use of the venous cuff for graft anastomosis. *Surg Gynecol Obstet* 1979;**148**:930.
- 15 Miller JH, Foreman RK, Ferguson L, Faris A. Interposition vein cuff for anastomosis of prostheses to small arteries. *Aust NZ J Surg* 1984;**54**:283–5.
- 16 Taylor RS, Loh A, McFarland RJ, Cox M, Chester JF. Improved technique for polytetrafluoroethylene bypass grafting: longterm results using anastomotic vein patches. *Br J Surg* 1992;**79**:348–54.
- 17 Tyrell MR, Wolfe JN. New prosthetic venous collar anastomotic technique: combining the best of other procedures. *Br J Surg* 1991;**78**:1016–7.
- 18 Kansal N, Pappas PJ, Gewertzman GA, Silva MB, Jamil Z, Lee BC, et al. Patency and limb salvage for polytetrafluoroethylene bypasses with vein interposition cuffs. *Ann Vasc Surg* 1999;**13**:386–432.
- 19 Stonebridge P, Prescott R, Ruckley C. Randomized trial comparing infrainguinal polytetrafluoroethylene bypass grafting with and without interposition vein cuff at the distal anastomosis. *J Vasc Surg* 1997;**26**:543–50.

- 20 Kreienberg PB, Darling C, Chang BB, Paty PK, Lloyd WE, Shah DM. Adjunctive techniques to improve patency of distal prosthetic bypass grafts: polytetrafluoroethylene with remote arteriovenous fistulae versus vein cuffs. *J Vasc Surg* 2000;**31**:696–701.
- 21 Kreienberg PB, Darling RC, Chang BB, Champagne BJ, Paty PK, Roddy SP, et al. Early results of a prospective randomized trial of spliced vein versus PTFE graft with a distal vein cuff for limb threatening ischemia. *J Vasc Surg* 2002;**35**:200–6.
- 22 Flis V, Pavlović M, Miksić K. The value of adjunctive vein patches to improve the outcome of femorodistal polytetrafluoroethylene bypass grafts. *Wien Klin Wochenschr* 2001;**113**(Suppl. 3):5–10.
- 23 Bellosta R, Luzzani L, Carugati C, Melloni C, Sarcina A. Which distal anastomosis should be used in PTFE femoro-tibial bypass?, **46(5)**. Torino: J Cardiovasc Surg; 2005 Oct. 499–503.
- 24 Heyligers JM, Arts CH, Verhagen HJ, de Groot PG, Moll FL. Improving small diameter vascular grafts: from the application of an endothelial cell lining to the construction of a tissue-engineered blood vessel. *Ann Vasc Surg* 2005;**19**:448–56.
- 25 Suggs WD, Enrique HF, DePalma RG. Vein cuff interposition prevents juxta-anastomotic hyperplasia. *Ann Surg* 1988;**207**:717–23.
- 26 Norberto JJ, Sidawy AN, Trad KS, Jones B, Neville RF, Najjar S, et al. The protective effect of vein cuffed anastomoses is not mechanical in origin. *J Vasc Surg* 1995;**21**:558–66.
- 27 Raptis S, Miller JH. Influence of a vein cuff on polytetrafluoroethylene grafts for primary femoropopliteal bypass. *Br J Surg* 1995;**82**:487–91.
- 28 Stonebridge PA, Naidu S, Colgan MP, Moore DJ, Shanik DG, McCollum PT. Tibial and peroneal artery bypasses using polytetrafluoroethylene with an interposition vein cuff. *J R Coll Surg Edinb* 2000;**45**:17–20.
- 29 Panneton JM, Hollier LH, Hofer JM. Multicenter randomized prospective trial comparing a precuffed polytetrafluoroethylene graft to a vein cuffed polytetrafluoroethylene graft for infragenicular arterial bypass. *Ann Vasc Surg* 2004;**18**:199–206.
- 30 Griffiths GD, Nagy J, Black D. Randomized clinical trial of distal anastomotic interposition vein cuff and infrainguinal polytetrafluoroethylene bypass grafting. *Br J Surg* 2004;**91**:560–2.
- 31 Oderich GS, Panneton JM, Yagubyan M, Bower TC, Hofer J, Noel AA, et al. Comparison of precuffed and vein cuffed expanded polytetrafluoroethylene grafts for infragenicular arterial reconstructions; a case matched study. *Ann Vasc Surg* 2005;**19**:49–55.
- 32 Lauterbach SR, Torres GA, Andros G, Oblath RW. Infragenicular polytetrafluoroethylene bypass with distal vein cuffs for limb salvage. *Arch Surg* 2005;**140**:487–94.
- 33 Yeung KK, Mills JL, Hughes JD, Berman SS, Gentile AT, Westerland A. Improved patency of infrainguinal polytetrafluoroethylene bypass grafts using a distal Taylor vein patch. *Am J Surg* 2001;**182**:578–83.