



The Relative Position of Paired Valves at Venous Junctions Suggests Their Role in Modulating Three-dimensional Flow Pattern in Veins

F. Lurie*, R.L. Kistner

Kistner Vein Clinic, and John A. Burns School of Medicine, University of Hawaii, 848 South Beretania Street, Suite 307, Honolulu, HI 96813, USA

WHAT THIS PAPER ADDS

- The knowledge of normal anatomical position and orientation of venous valves should be helpful in making surgical decisions during valve reconstructions, and for development of new valve-replacement devices.

ARTICLE INFO

Article history:

Received 4 April 2012

Accepted 22 June 2012

Available online 21 July 2012

Keywords:

Venous valve
Venous hemodynamics
Venous disease
Veins
Anatomy
Physiology

ABSTRACT

Purpose: The aim of the study is to investigate the relative position of orifices of two valves within the most proximal segments of the great saphenous vein (GSV), and the femoral vein (FV).

Methods: A total of 15 volunteers with no signs or symptoms of venous disease and 13 unaffected limbs of patients with unilateral primary chronic venous disease (CVD) were included. Two most proximal valves of the GSV and the FV were identified. The angle between the two valves, and the distance between the valves were measured.

Results: The mean distance between the two valves in the GSV was 3.8 ± 0.4 cm, and in the FV was 4.6 ± 0.3 cm. In one limb, the distance between the FV valves was 1 cm less than GSV valves, and in two limbs the distances were equal. In the remaining 12 limbs available for comparison, the valves in the FV were 1–2 cm further apart compared to the GSV ($P = 0.002$, paired *t*-test). All studied pairs of valves were positioned at a minimum 60° angle to each other. The mean angle between the two valves was $84.3 \pm 8.4^\circ$ in the GSV, and $88.3 \pm 6.7^\circ$ in the FV ($P = 0.24$). The angle between the two valves correlated with the distance between the valves ($r = 0.68$, $P = 0.000005$). No significant relations were found between the diameter of the studied vein, and the angle between the two valves. There was no difference in valve orientation between volunteers and unaffected limbs of the patients with CVD.

Conclusion: When two valves are present in the areas of venous junctions, they consistently positioned at a significant angle to each other. A hypothesis that venous valves at the junctions increase efficiency of venous return by creating a helical flow pattern can be postulated and deserves further investigation.

© 2012 European Society for Vascular Surgery. Published by Elsevier Ltd. All rights reserved.

Dysfunction of the venous valves and consequent venous reflux are major pathological findings in primary chronic venous disease (PCVD). For this reason, surgical treatment of PCVD is generally aimed to eliminate the reflux by ligation of the incompetent vein, ablation of the refluxing segment (mechanical, chemical or thermal), redirecting blood flow into a competent vein (transposition) and repairing the incompetent valve or replacing it with a transplant. Replacement venous valve prosthesis is currently not

available, but is likely to be developed in the future. In addition, recent attempts to create an autologous neo-valve have been reportedly successful.¹

Possibility of such advanced options raises multiple questions, among which is where to place, and how to position the prosthesis or neo-valve. Specific pathological and haemodynamic features that are present in affected extremities are definitely the main determinants of a site for the valve placement, but knowledge of normal anatomical position and orientation of venous valves may be helpful in making such a decision. The literature that addresses these questions is scarce,² but some information is available, and relatively well established. Despite significant individual variability,

* Corresponding author. Tel.: +1 808 532 8346; fax: +1 808 532 2240.

E-mail addresses: flurie@hawaii.edu, tedlurie@yahoo.com (F. Lurie).

valves are consistently located at specific locations in the veins of the leg,^{2–4} and in the areas of major junctions, they are usually present in pairs 3–5 cm apart from each other.^{5–8} The relations between density and position of venous valves in different veins showed that they always affect local blood flow.^{9,10} Therefore, constant duplication of valves near the junctions is likely to have a functional significance to the blood flow in these segments.

One of the effects of venous valves is the dramatic change of the three-dimensional velocity profile of the blood flow due to the shape and size of the orifice.^{11–13} Two closely located valves may have a combined effect on the flow if the relative orientation of their orifices has reasonable consistency between individuals. We were unable to find any studies that investigated the orientation of valve orifices in relation to the vein axis, or relative position of orifices of two valves within the venous segment. This study was undertaken to address this gap in anatomical information.

Methods

Twenty-four healthy volunteers with no signs or symptoms of venous disease and 20 unaffected limbs of patients with unilateral PCVD were screened for the presence of two valves in the proximal great saphenous vein (GSV). Fifteen volunteers and 13 patients were selected for the study. Only extremities that have the most proximal valve located more than 1 cm from the sapheno-femoral junction (SFJ) were included, due to limited ability to measure the angle of the orifice in more proximally located valves. All included extremities had no evidence of venous disorders by duplex scan.

Duplex ultrasound scans were performed using GE Logiq-700 and Logiq-7 systems with a 5–10 MHz linear array probe. Subjects were placed in a 15° head-up position at room temperature. The valves were identified using B-mode and B-Flow mode, and images were acquired with the probe in transverse position perpendicular to the axis of the vein. After imaging of the distal of the two valves, the probe was moved along the axis of the vein without changing its angle until the proximal of the two valves was identified. B-flow mode was used to precisely position the probe at the orifice of the valve. The angle between the long axis of the valve's orifice and the vertical line corresponded to the direction of the ultrasound beam was measured for each valve, and the angle between the two valves' orifices was calculated (Fig. 1). The probe then was turned in the longitudinal position along the axis of the vein, and the distance between the valves was measured. If the distance exceeded the length of the probe, the virtual convex function was used. This was sufficient for measuring distance without moving the probe in all cases.

In addition to the GSV valves, the two most proximal valves in the femoral vein (FV) were identifiable in 8 legs of the 15 volunteers and in 7 legs of the 10 patients. The same measurements were performed for this pair of valves in each available extremity.

The protocol was approved by the Institutional Review Board of Straub Clinic and Hospital. A pilot study using a phantom imitating two valves was performed prior to implementing this protocol. The accuracy of angle measurements was tested and showed mean error of measurements $1.6 \pm 0.8^\circ$, and the difference between ultrasound measurement and true angle not exceeding 3° .

Results

All studied valves were located between 3 and 5 cm apart. The mean distance between the two valves in the GSV was 3.8 ± 0.4 cm, and in the FV it was 4.6 ± 0.3 cm. In one limb, the distance between the FV valves was 1 cm less than between the GSV valves, and in two limbs the distances were equal. In remaining 12 limbs available

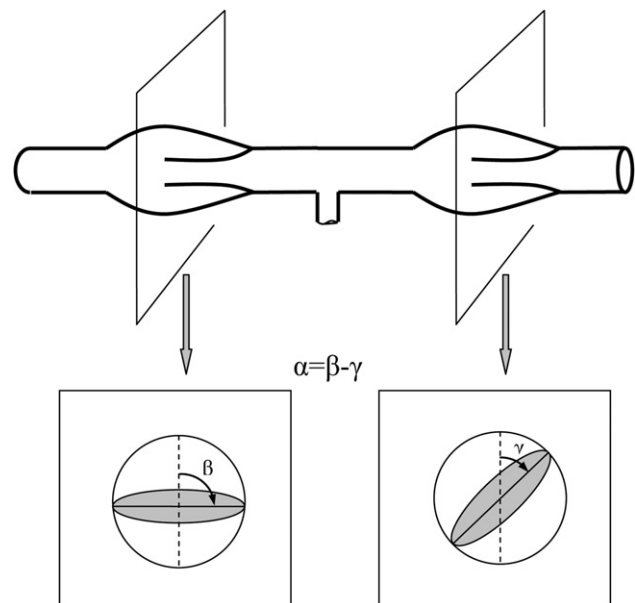


Figure 1. Measuring the angle between orifices of two valves. The angle between the vertical line corresponding to the direction of the ultrasound beam was measured in each trans-sectional image of the valve's orifice (angles β and γ). The difference between these two angles is the angle between the two orifices (angle α).

for comparison, the valves in the FV were 1–2 cm further apart compared to the GSV ($P = 0.002$, paired *t*-test).

All studied pairs of valves were positioned at a minimum 60° angle to each other. The mean angle between the two valves was $84 \pm 8^\circ$ in the GSV, and $88 \pm 7^\circ$ in the FV ($P = 0.24$). The frequency distributions of the distance and angle are shown on the histograms (Fig. 2). The magnitude of the angle between the two valves correlated well with the distance between the valves ($r = 0.68$, $P < 0.001$, Fig. 3). No significant relations were found between the diameter of studied vein, and the angle between the two valves. There was no difference in valve orientation between volunteers and unaffected limbs of the patients with CVD.

Discussion

This study demonstrated that when two valves are present in the areas of venous junctions, they consistently positioned at a significant angle to each other. This angle correlates with the distance between the two valves, and does not correlate with the size of the vein. The impact of such anatomical configuration on the flow of blood can be significant. Previous studies showed that when the venous valve opens, the leaflets do not go all the way against the wall of the vessel, even at high flow rates.^{14–18} At the time of maximal opening, the valve has a funnel shape with an elliptic-shaped orifice (Fig. 4). The long axis of this ellipse is the vein diameter, and the short axis is about 60–70% of the vein diameter.¹¹ When blood passes through that funnel, it forms a jet with higher velocities in the centre, and a cross-section similar to the shape of the orifice. A second downstream valve, if positioned at an angle to the first valve, introduces rotational momentum to the blood stream, potentially generating helical flow (Fig. 5).

Spiral or helical flow is a common pattern of flow in the circulatory system. It has been identified in normal arteries,^{19–22} and lack of such pattern was found in pathological conditions.^{23,24} Biomechanical studies suggest that helical flow decreases dissipation of energy by limiting flow instability,^{25,26} and represents natural optimisation of fluid transport in the cardiovascular

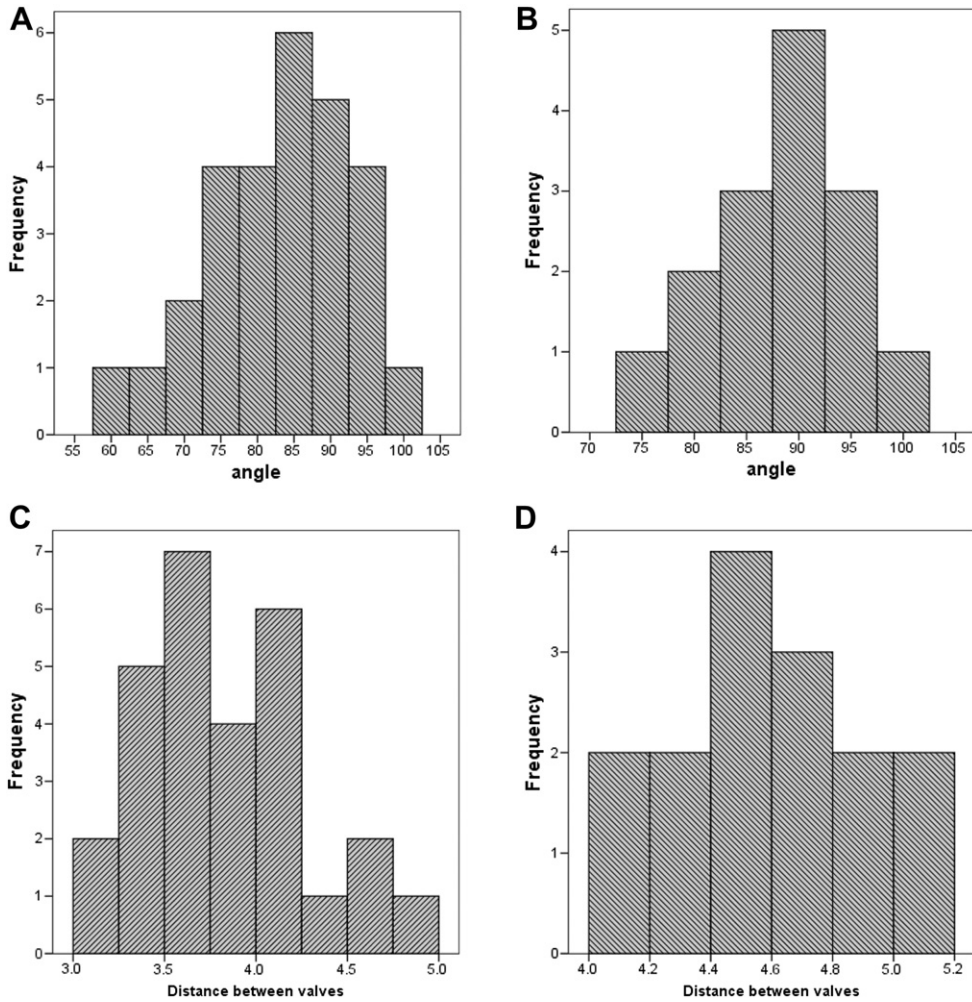


Figure 2. Histograms of frequency distributions of angles (degrees) between the two valves in the Great Saphenous Vein (GSV) (A) and the Femoral Vein (FV) (B), and of the distances (cm) between these valves in the GSV (C) and FV (D).

system.²⁷ Three-dimensional patterns of blood flow in veins have not been described in contemporary literature; however, the existence of helical flow in veins is biologically plausible. If such a pattern exists, it may provide haemodynamic benefits that compensate for resistance introduced by venous valves, and contribute to more effective outflow. Thus, a hypothesis can be reasonably formulated that venous valves at the junctions increase efficiency of venous return by creating a helical flow pattern.

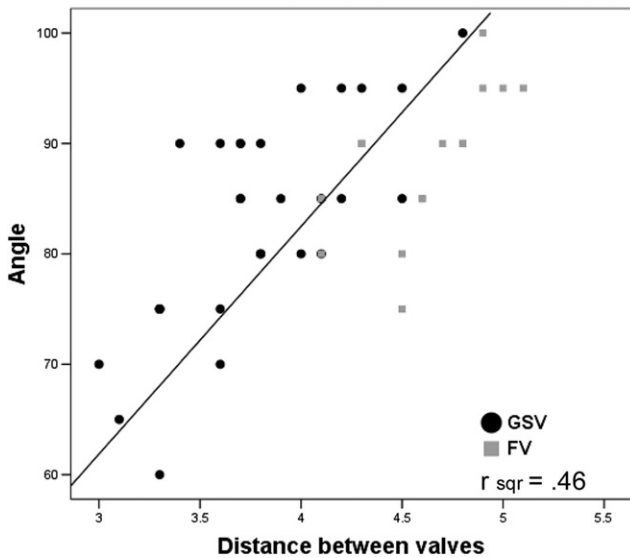


Figure 3. Relations between the distance (cm) between the two valves, and the angle (degrees) between their orifices.

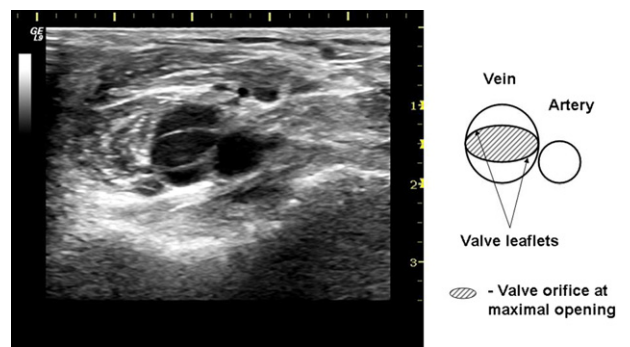


Figure 4. Orifice of venous valve. Ultrasound image (left) and a diagram (right) of a cross-section of vein at the level of valve orifice shows elliptical shape of the orifice at the time of maximal opening of the valve.

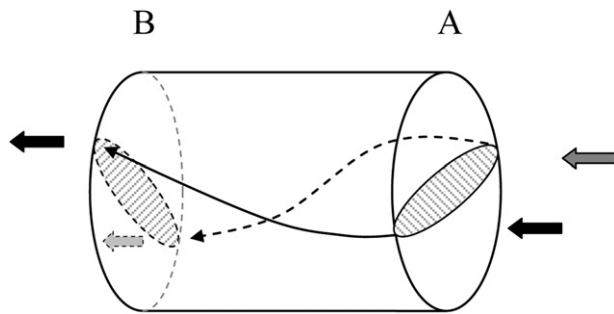


Figure 5. Influence of relative position of the paired valves on three-dimensional flow pattern. A second downstream valve (B) is positioned at an angle to the first valve (A) creating rotational momentum to the blood stream, and generating helical flow.

The advantage of using ultrasound imaging in this study compared to anatomical dissections is that the valves have been imaged *in situ* without distorting their position. However, the use of ultrasound introduced significant limitations. Not all valves can be visualised by an ultrasound scan with sufficient quality, leaving the true prevalence of described anatomy unknown. Movements and positioning of the ultrasound probe are highly operator dependent, which introduces unavoidable error to angle measurements. In addition, only two venous segments were investigated in this study, and generalisation to other parts of the venous system awaits future exploration. Despite these limitations, the magnitude of the angle between two valves and consistency of valves' orientation among the individuals leaves little doubt that the findings are not accidental. Future investigation into three-dimensional flow patterns in veins is needed to test the hypothesis that valves positions influence efficiency of outflow. If confirmed, this information can significantly influence surgical decisions regarding how and where to position a prosthetic valve, or create an autologous neo-valve.

Conflict of Interest

None.

Funding

None.

References

- Maleti O, Lugli M. Neovalve construction in postthrombotic syndrome. *J Vasc Surg* 2006;**43**:794–9.
- Moore HM, Gohel M, Davies AH. Number and location of venous valves within the popliteal and femoral veins: a review of the literature. *J Anat* 2011;**219**:439–43.
- Powell T, Lynn RB. The valves of the external iliac, femoral, and upper third of the popliteal veins. *Surg Gynecol Obstet* 1951;**92**:453–5.
- Basmajian JV. The distribution of valves in the femoral, external iliac, and common iliac veins and their relationship to varicose veins. *Surg Gynecol Obstet* 1952;**95**:537–42.
- Caggiati A, Bergan JJ, Gloviczki P, Eklof B, Allegra C, Partsch H. Nomenclature of the veins of the lower limb: extensions, refinements, and clinical application. *J Vasc Surg* 2005;**41**:719–24.
- Muhlberger D, Morandini L, Brenner E. Venous valves and major superficial tributary veins near the saphenofemoral junction. *J Vasc Surg* 2009;**49**:1562–9.
- Schweighofer G, Muhlberger D, Brenner E. The anatomy of the small saphenous vein: fascial and neural relations, saphenofemoral junction, and valves. *J Vasc Surg* 2010;**51**:982–9.
- Tasch C, Brenner E. The ostial valve of the great saphenous vein. *Phlebology* 2012;**27**:179–83.
- Calota F, Mogoanta SS, Vasilescu MM, Vasile I, Pasalega M, Stoicea MC, et al. The valvular segment of the lower limbs venous system: anatomical, physiological and physiopathological aspects. *Rom J Morphol Embryol* 2010;**51**:157–61.
- Maros T. Data regarding the typology and functional significance of the venous valves. *Morphol Embryol (Bucur)* 1981;**27**:195–214.
- Puggioni A, Lurie F, Kistner RL, Eklof B. How often is deep venous reflux eliminated after saphenous vein ablation? *J Vasc Surg* 2003;**38**:517–21.
- Buescher CD, Nachiappan B, Brumbaugh JM, Hoo KA, Janssen HF. Experimental studies of the effects of abnormal venous valves on fluid flow. *Biotechnol Prog* 2005;**21**:938–45.
- Karino T, Motomiya M. Flow through a venous valve and its implication for thrombus formation. *Thromb Res* 1984;**36**:245–57.
- Carrier EB. Observations of living cells in the bat's wing. In: *Physiological papers dedicated to Prof August Krogh*. London: WM Heinemann Ltd; 1926. p. 1–9.
- Whitney DG, Kahn EM, Estes JW. Valvular occlusion of the arterialized saphenous vein. *Am Surg* 1976;**42**:879–87.
- Clifford PC, Woodcock JP, Baird RN. The fate of the valves of autogenous vein grafts. *Br J Radiol* 1981;**54**:348–50.
- McCaughan Jr JJ, Walsh DB, Edgcomb LP, Garrett HE. In vitro observations of greater saphenous vein valves during pulsatile and nonpulsatile flow and following lysis. *J Vasc Surg* 1984;**1**:356–61.
- Lurie F, Kistner RL, Eklof B, Kessler D. Mechanism of venous valve closure and role of the valve in circulation: a new concept. *J Vasc Surg* 2003;**38**:955–61.
- Mohiaddin RH, Yang GZ, Kilner PJ. Visualization of flow by vector analysis of multidirectional cine MR velocity mapping. *J Comput Assist Tomogr* 1994;**18**:383–92.
- Kilner PJ, Yang GZ, Mohiaddin RH, Firmin DN, Longmore DB. Helical and retrograde secondary flow patterns in the aortic arch studied by three-directional magnetic resonance velocity mapping. *Circulation* 1993;**88**:2235–47.
- Stonebridge PA, Brophy CM. Spiral laminar flow in arteries? *Lancet* 1991;**338**:1360–1.
- Hoskins PR, Fleming A, Stonebridge P, Allan PL, Cameron D. Scanplane vector maps and secondary flow motions in arteries. *Eur J of Ultrasound* 1994;**159**–69.
- Bogren HG, Mohiaddin RH, Yang GZ, Kilner PJ, Firmin DN. Magnetic resonance velocity vector mapping of blood flow in thoracic aortic aneurysms and grafts. *J Thorac Cardiovasc Surg* 1995;**110**:704–14.
- Houston JG, Gandy SJ, Milne W, Dick JB, Belch JJ, Stonebridge PA. Spiral laminar flow in the abdominal aorta: a predictor of renal impairment deterioration in patients with renal artery stenosis? *Nephrol Dial Transpl* 2004;**19**:1786–91.
- Caro CG, Doorly DJ, Tarnawski M, Scott KT, Long Q, Dumoulin CD. Non-planar curvature and branching of arteries and non-planar-type flow. *Proc Royal Society London A* 1996;**452**:185–97.
- Morbiducci U, Ponzini R, Rizzo G, Cadioli M, Esposito A, De Cobelli F, et al. In vivo quantification of helical blood flow in human aorta by time-resolved three-dimensional cine phase contrast magnetic resonance imaging. *Ann Biomed Eng* 2009;**37**:516–31.
- Morbiducci U, Ponzini R, Rizzo G, Cadioli M, Esposito A, Montecchi FM, et al. Mechanistic insight into the physiological relevance of helical blood flow in the human aorta: an in vivo study. *Biomech Model Mechanobiol* 2011;**10**:339–55.