

- 30 Allison MA, Kwan K, DiTomasso D, Wright CM, Criqui MH. The epidemiology of abdominal aortic diameter. *J Vasc Surg* 2008;**48**(1):121–7.
- 31 Thilo F, Vorderwülbecke BJ, Marki A, Krueger K, Liu Y, Baumunk D, et al. Pulsatile atheroprone shear stress affects the expression of transient receptor potential channels in human endothelial cells. *Hypertension* 2012;**59**(6):1232–40.
- 32 Chatzizisis YS, Giannoglou GD. Coronary hemodynamics and atherosclerotic wall stiffness: a vicious cycle. *Med Hypotheses* 2007;**69**:349–55.
- 33 The International AAA Screening Group, Björck M, Bown MJ, Choke E, Earnshaw J, Flørenes T, Glover M, et al. International update on screening for abdominal aortic aneurysms: issues and opportunities. *Eur J Vasc Endovasc Surg* 2015;**49**:113–5.
- 34 Svensjö S, Björck M, Gürtelschmid M, Djavani Gidlund K, Hellberg A, Wanhainen A. Low prevalence of abdominal aortic aneurysm among 65 year old Swedish men indicates a change in the epidemiology of the disease. *Circulation* 2011;**124**:1118–23.
- 35 Conway AM, Malkawi AH, Hinchliffe RJ, Holt PJ, Murray S, Thompson MM, et al. First-year results of a national abdominal aortic aneurysm screening programme in a single centre. *Br J Surg* 2012;**99**:73–7.
- 36 Svensjö S, Björck M, Wanhainen A. Current prevalence of AAA in 70-year old women. *Br J Surg* 2013;**100**:367–72.

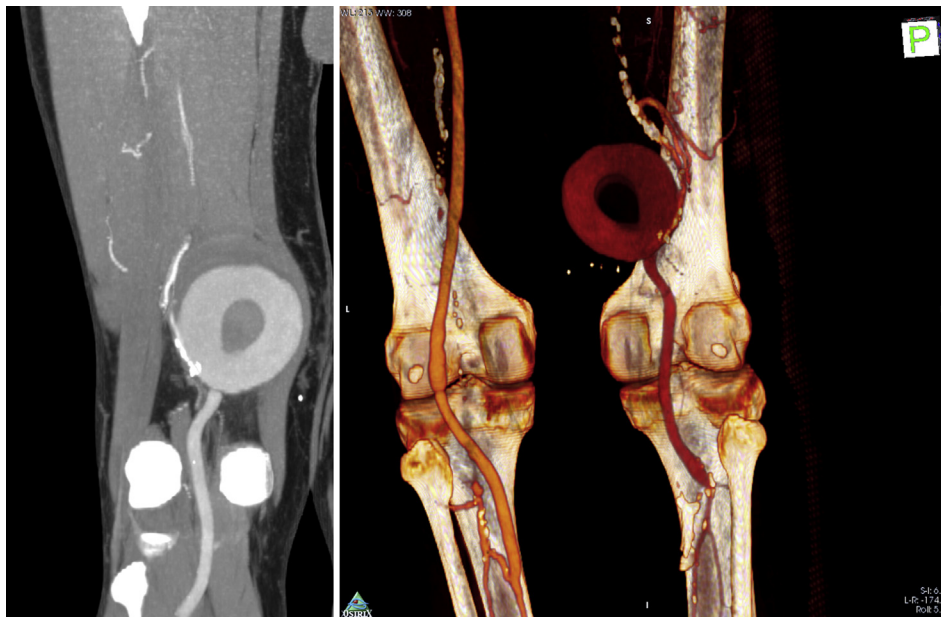
Eur J Vasc Endovasc Surg (2015) 50, 721

## COUP D'OEIL

# O-shaped, Non-pulsatile Distal Superficial Femoral Artery Pseudoaneurysm in the Presence of Proximal Occlusion

N. Kontopodis, C.V. Ioannou\*

Vascular Surgery Unit, Department of Cardiothoracic and Vascular Surgery, University Hospital of Heraklion, Greece



A 69 year old patient who, 10 years previously, had undergone popliteal artery aneurysm exclusion with a distal superficial femoral (SFA) to below knee popliteal artery bypass using the great saphenous vein presented with a non-pulsatile mass in the lower thigh. Computed tomography angiography revealed a “contrast ring” or “O” shaped 6.5 cm pseudoaneurysm at the proximal anastomosis fed through a large collateral via the profunda, in the presence of SFA occlusion. Pressurization of this unique pseudoaneurysm was considered low and thus it was non-pulsatile, thereby obscuring clinical evaluation. The pseudoaneurysm was resected and a bypass from the proximal SFA to the previous venous conduit below the knee was performed.

\* Corresponding author. Vascular Surgery Unit, Department of Cardiothoracic and Vascular Surgery, University Hospital of Heraklion, PO Box 1352, 711 10, Heraklion, Greece. Tel.: +30 281 340 2379; fax: +30 2810 375365.

E-mail address: [ioannou@med.uoc.gr](mailto:ioannou@med.uoc.gr) (C.V. Ioannou).

1078-5884/© 2015 European Society for Vascular Surgery. Published by Elsevier Ltd. All rights reserved.

<http://dx.doi.org/10.1016/j.ejvs.2015.09.028>