

- patients undergoing endovascular aneurysm repair. *J Cardiovasc Surg* 2004;**45**(4):367–74.
- 25 Fairman RM, Velazquez OC, Carpenter JP, Woo E, Baum RA, Golden MA, et al. Midterm pivotal trial results of the Talent Low Profile System for repair of abdominal aortic aneurysm: analysis of complicated versus uncomplicated aortic necks. *J Vasc Surg* 2004;**40**(6):1074–82.
- 26 Leurs LJ, Kievit J, Dagnelie PC, Nelemans PJ, Buth J. Influence of infrarenal neck length on outcome of endovascular abdominal aortic aneurysm repair. *J Endovasc Ther* 2006;**13**(5): 640–8.
- 27 Hovsepian DM, Hein AN, Pilgram TK, Cohen DT, Kim HS, Sanchez LA, et al. Endovascular abdominal aortic aneurysm repair in 144 patients: correlation of aneurysm size, proximal aortic neck length, and procedure-related complications. *J Vasc Interv Radiol* 2001;**12**(12):1373–82.
- 28 AbuRahma AF, Campbell J, Stone PA, Nanjundappa A, Jain A, Dean LS, et al. The correlation of aortic neck length to early and late outcomes in endovascular aneurysm repair patients. *J Vasc Surg* 2009;**50**(4):738–48.
- 29 Stather PW, Wild JB, Sayers RD, Bown MJ, Choke E. Endovascular aortic aneurysm repair in patients with hostile neck anatomy. *J Endovasc Ther* 2013;**20**(5):623–37.
- 30 Hager ES, Cho JS, Makaroun MS, Park SC, Chaer R, Marone L, et al. Endografts with suprarenal fixation do not perform better than those with infrarenal fixation in the treatment of patients with short straight proximal aortic necks. *J Vasc Surg* 2012;**55**(5):1242–6.
- 31 Greenberg R, Fairman R, Srivastava S, Criado F, Green R. Endovascular grafting in patients with short proximal necks: an analysis of short-term results. *Cardiovasc Surg* 2000;**8**(5):350–4.

Eur J Vasc Endovasc Surg (2017) 54, 11

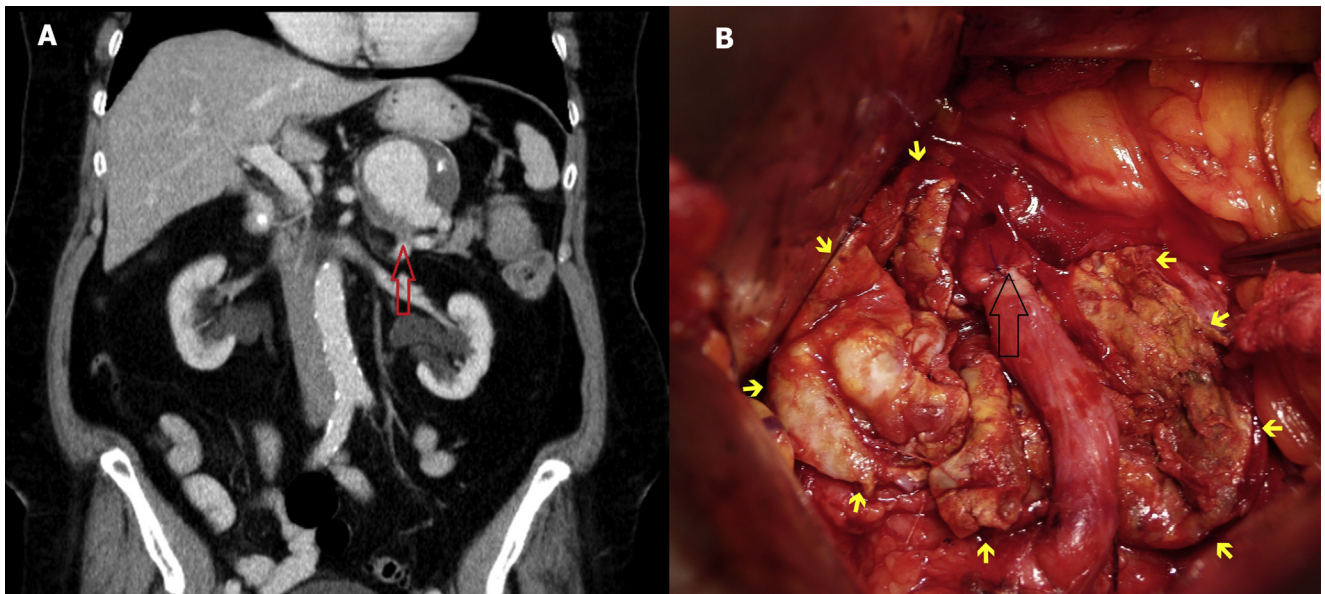
COUP D'OEIL

Surgical Treatment of Splenic Artery Aneurysm

P. Berek ^{a,b}, P. Štefanič ^{a,b,*}

^aClinic of Vascular Surgery, East Slovak Institute of Cardiovascular Diseases (VÚSCH, a.s.), Košice, Slovak Republic

^bFaculty of Medicine, Pavol Jozef Šafárik University, Košice, Slovak Republic



A 73 year old patient was admitted with back pain in the thoracic and lumbar area; CT angiography revealed a 60×70 mm saccular splenic artery aneurysm (SAA) (panel A). The symptomatic SAA was repaired via a left subcostal incision, with end to end splenic artery reconstruction precluding the need for great saphenous vein or prosthetic graft interposition (panel B, hollow black arrow = anastomosis, yellow arrows = margins of the open SAA sac). The patient was discharged home 8 days after the operation in a clinically stable condition and with relief of his back pain.

* Corresponding author. Clinic of Vascular Surgery, East Slovak Institute of Cardiovascular Diseases (VÚSCH, a.s.), Ondavská 8, Košice, 040 01, Slovak Republic.

E-mail address: stefanic.peter8@gmail.com (P. Štefanič).

1078-5884/© 2017 European Society for Vascular Surgery. Published by Elsevier Ltd. All rights reserved.

<http://dx.doi.org/10.1016/j.ejvs.2017.02.019>