

- 37 Reason J. Beyond the organisational accident: the need for "error wisdom" on the frontline. *Qual Saf Health Care* 2004 Dec;**13**(Suppl 2):ii28–33. <http://dx.doi.org/10.1136/qshc.2003.009548>.
- 38 Hull L, Bicknell C, Patel K, Vyas R, Van Herzelee I, Sevdalis N, et al. Content validation and evaluation of an endovascular teamwork assessment tool. *Eur J Vasc Endovasc Surg* 2016;**52**(1):11–20. <http://dx.doi.org/10.1016/j.ejvs.2015.12.044>.
- 39 Undre S, Sevdalis N, Healey AN, Darzi A, Vincent CA. Observational teamwork assessment for surgery (OTAS): refinement and application in urological surgery. *World J Surg* 2007;**31**(7):1373–81.
- 40 Sevdalis N, Davis R, Koutanji M, Undre S, Darzi A, Vincent CA. Reliability of a revised NOTECHS scale for use in surgical teams. *Am J Surg* 2008;**196**:184–90.
- 41 Rudarakanchana N, Van Herzelee I, Bicknell CD, Riga CV, Rolls A, Cheshire NJW, et al. Endovascular repair of ruptured abdominal aortic aneurysm: technical and team training in an immersive virtual reality environment. *Cardiovasc Intervent Radiol* 2014;**37**:920–7. <http://dx.doi.org/10.1007/s00270-013-0765-1>.
- 42 Sodergren MH, Darzi A. Surgical innovation and the introduction of new technologies. *Br J Surg* 2013;**100**:12–3. <http://dx.doi.org/10.1002/bjs.9164>.
- 43 Haynes AB, Weiser TG, Berry WR, Lipsitz SR, Breizat A-HS, Dellinger EP, et al. A surgical safety checklist to reduce morbidity and mortality in a global population. *N Engl J Med* 2009;**360**(5):491–9. <http://dx.doi.org/10.1056/NEJMsa0810119>.
- 44 Harkin DW, Beard J, Wyatt M, Shearman C. *Vascular surgery UK workforce report*. London: Vascular Society; 2014.

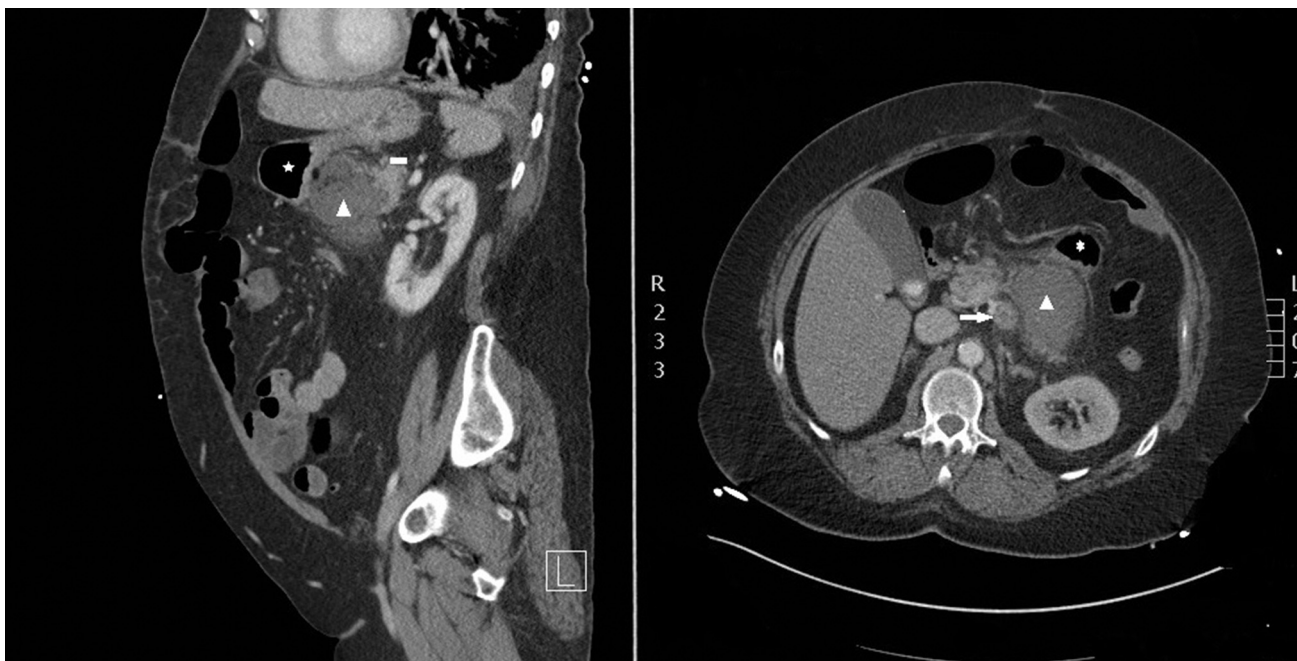
Eur J Vasc Endovasc Surg (2017) 54, 93

COUP D'OEIL

Gastric erosion by abscess 15 years after mesenteric bypass surgery

H. Mufty^{*}, I. Fourneau

Department of Vascular Surgery, University Hospitals Leuven, Belgium



A 59 year old woman presented with fever, urinary frequency, and lower backache. A contrast enhanced abdominal computed tomography scan revealed a mass (arrow head) between the stomach (asterisk), pancreas (rectangle), and a thrombosed aorto-mesenteric Dacron graft (arrow), which had been created 15 years previously for abdominal angina. Radiologists of different subspecialties could not reach consensus on the aetiology. Intra-operatively, despite omental covering during the last operation, a thick walled abscess with gastric erosion was seen. The graft was successfully removed without the need for replacement thanks to a second patent retrograde mesenteric bypass that was created 8 years previously without visible signs of infection.

* Corresponding author.

E-mail address: hozan.mufty@uzleuven.be (H. Mufty).

1078-5884/© 2017 European Society for Vascular Surgery. Published by Elsevier Ltd. All rights reserved.

<http://dx.doi.org/10.1016/j.ejvs.2017.02.034>