Eur J Vasc Endovasc Surg (2018) 55, 170—176

Fenestrated Thoracic Endovascular Aortic Repair Using Physician Modified Stent Grafts for Acute Type B Aortic Dissection with Unfavourable Landing Zone

Jiechang Zhu [a], Lujing Zhao [b], Xiangchen Dai [a,*], Yudong Luo [a], Hailun Fan [a], Zhou Feng [a], Yiwei Zhang [a], Fanguo Hu [a]

[a] Department of General Surgery, General Hospital of Tianjin Medical University, Tianjin, PR China
[b] Emergency Department, Tianjin 4th Centre Hospital, Tianjin, PR China

WHAT THIS PAPER ADDS

The study indicates that fTEVAR with PMSGs may be a viable alternative for ABAD patients with unfavourable proximal landing zones, unable to wait for a custom made fenestrated device.

Objectives: The aim was to evaluate the early results of fenestrated thoracic endovascular aortic repair (fTEVAR) using physician modified stent grafts (PMSGs) to revascularise aortic branches for acute type B aortic dissection (ABAD) with unfavourable proximal landing zone.

Methods: Twenty consecutive patients who underwent fenestrated TEVAR using PMSGs between November 2015 and December 2016 were retrospectively reviewed. Pre-, intra-, and post-operative clinical data were recorded.

Results: The median patient age was 53 years (range, 18—83 years), and 16 of the 20 (80%) patients were men. Indications were complicated ABAD with unfavourable proximal landing zones, including inadequate proximal landing zone ($n = 4$), retrograde dissection extending to the left subclavian artery (LSA) ($n = 13$), and retrograde haematoma involving the LSA ($n = 3$). Twenty PMSGs (Medtronic Valiant stent grafts, $n = 4$; Relay thoracic stent grafts, $n = 10$; Ankura thoracic stent grafts, $n = 6$) were deployed. One LSA fenestration was created in 19 patients, and one LSA fenestration combined with a left common carotid artery (LCCA) scallop was created in one patient. Branch stents consist of a covered stent for the LSA ($n = 7$), an uncovered stent for the LSA ($n = 14$), and an uncovered stent for the LCCA ($n = 1$). The median duration for stent graft modifications was 40 min (range 30—60 min). The mean interval between symptom onset and treatment was 5 ± 3 days (range, 1—10 days). The initial technical success rate was 90% (18 of 20). Partial coverage of the LCCA in one patient resolved after uncovered chimney stent implantation in the LCCA. Type III endoleak between the LSA covered stent and the PMSG occurred in this patient 1 week post fTEVAR and resolved after re-intervention with deployment of an Amplatzer occluder device across the site of the leak. A chimney stent was deployed to solve the misalignment of the LSA in another patient. The mean operation time was 101 ± 48 min, and fluoroscopy time was 24 ± 16 min. There were no in hospital deaths and no peri-operative neurological complications. The median length of stay was 9 ± 6 days (range, 5—26 days). One patient had a left brachial artery (LBA) pseudoaneurysm at the puncture site that required open repair. One patient presented renal deterioration post-operatively and recovered uneventfully after conservative therapy. All patients survived at a mean follow-up of 6.95 months (range, 2—14 months). During follow-up, no post-operative complications occurred and all target vessels remained patent. No fenestration related Type I or III endoleaks were observed.

Conclusions: fTEVAR using PMSGs may be a viable alternative for patients who present with ABAD without healthy proximal landing zones and who are unable to wait for a custom made fenestrated device.

© 2017 Published by Elsevier Ltd on behalf of European Society for Vascular Surgery.

Article history: Received 2 April 2017, Accepted 10 November 2017, Available online 12 December 2017

Keywords: Type B dissection, Left subclavian artery, Fenestration, Thoracic endovascular aortic repair

INTRODUCTION

Aortic dissection is one of the most severe presentations of acute aortic syndrome. Data from the International Registry of Aortic Dissection (IRAD) showed high mortality, with 25% of patients dying within 3 years of acute type B dissection (ABAD).[1] Thoracic endovascular aortic repair (TEVAR) has

* Corresponding author. Department of General Surgery, General Hospital of Tianjin Medical University, Tianjin, 300052, PR China.
E-mail address: 13302165917@163.com (Xiangchen Dai).

1078-5884/© 2017 Published by Elsevier Ltd on behalf of European Society for Vascular Surgery.
https://doi.org/10.1016/j.ejvs.2017.11.012

become the optimal choice to treat complicated ABAD, with lower mortality and morbidity than conventional open surgical repair.[2] Left subclavian artery (LSA) coverage has been reported in 50% of patients undergoing TEVAR to treat acute aortic syndromes.[3] In these situations, currently approved devices are normally deployed over the LSA to obtain an adequate and a favourable proximal sealing zone. Rehman et al.[4] showed that isolated LSA coverage without revascularisation in the presence of aortic dissection resulted in a significant increase in the prevalence of left arm ischaemia from 0.0% to 4.0%, stroke from 1.4% to 9.0%, and endoleak from 4.0% to 29.3%. The reconstruction of the LSA destined to be covered during TEVAR becomes necessary to lower the risk of the complications mentioned above.

Several strategies have been proposed for revascularisation of the LSA, including debranching TEVAR, the chimney technique, prefabricated branched endograft deployment, or laser graft fenestration in situ.[5–8] These options have limitations in some situations. Manufactured fenestrated stent grafts are not suitable for patients in an emergency setting because of high device costs and long manufacturing delays. An alternative option is the physician modified fenestrated stent graft (PMSG), which may be suitable for

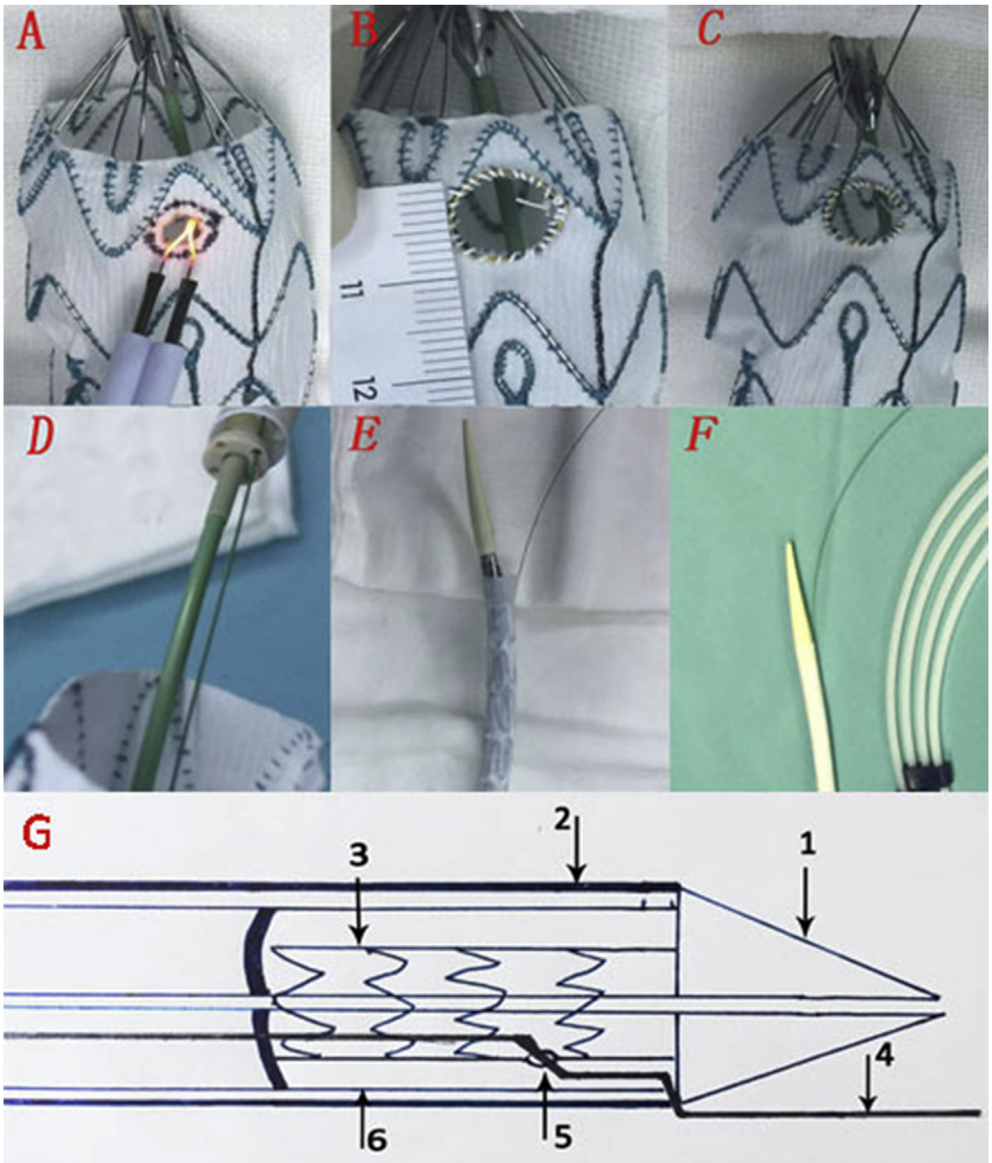

Figure 1. Device modification. (A) The Relay thoracic stent graft was fully unsheathed. The left subclavian artery (LSA) fenestration was created using an ophthalmology cautery (Oasis Medical, Glendora, CA, USA). (B) The LSA fenestration was reinforced using the loop of a snare (Amplatz Goose Neck, ev3, Plymouth, MN, USA), fixed to the fabric with a continuous running suture of CV-5 (Gore, Flagstaff, AZ, USA) about 8 mm in diameter. (C,D) A 300 cm, 0.014 inch nitinol guidewire (ASAHI, Nagoya, Aichi, Japan) was used to pass through the LSA fenestration into the endograft and the stiff tip of the guidewire was pushed about 40 cm into the inner secondary sheath of the device. (E,F) The stent graft was reloaded in the inner secondary sheath and the primary outer sheath. (G) The picture shows the schematic diagram of the modified Relay thoracic stent graft delivery system: (1) tapered tip, (2) the outer primary introducing sheath, (3) endograft, (4) pre-loaded guidewire, (5) fenestration, and (6) the inner secondary soft sheath.

LSA revascularisation during TEVAR in acute situations. Joseph et al.[9] described a technique of PMSG with externalised guidewire to revascularise a LSA during repair of descending thoracic aortic aneurysm in a young patient. Some medical centres have reported good short-term results of fenestrated stent graft for thoracic aortic aneurysm,[10] but there is a lack of data on their applicability for ABAD. In this study, the initial experience of fenestrated TEVAR using PMSGs to revascularise the LSA for ABAD with unfavourable proximal landing zone is described.

METHODS

This study was performed with approval of the Tianjin Medical University General Hospital Institutional Review Board. Informed consent for the procedure was obtained from all those participating.

Patient identification

Between November 2015 and December 2016, a cohort of 20 consecutive patients with ABAD underwent fenestrated TEVAR using PMSGs at the Tianjin Medical University General Hospital, and patient demographics, surgical indications, operative and post-operative details, follow-up, and outcomes were retrospectively reviewed.

The indication for endovascular surgery in this study was complicated ABAD with unfavourable proximal landing zones, including inadequate proximal landing zone (<15 mm from the opening of the LSA to the proximal entry tear), retrograde dissection extending to the LSA, or retrograde haematoma involving the LSA. During the period of this study, six patients with uncomplicated ABAD with involvement of the LSA received medical treatment. 15 patients with ABAD without LSA involvement were excluded. Nine underwent medical treatment and the other six underwent TEVAR.

Pre-operative evaluation and imaging

Pre-operative imaging was performed by computed tomography angiography (CTA) to determine the classification of the dissection, location of the proximal entry tear, and the involvement of the arch. Imaging measurement was performed using dedicated three dimensional vascular

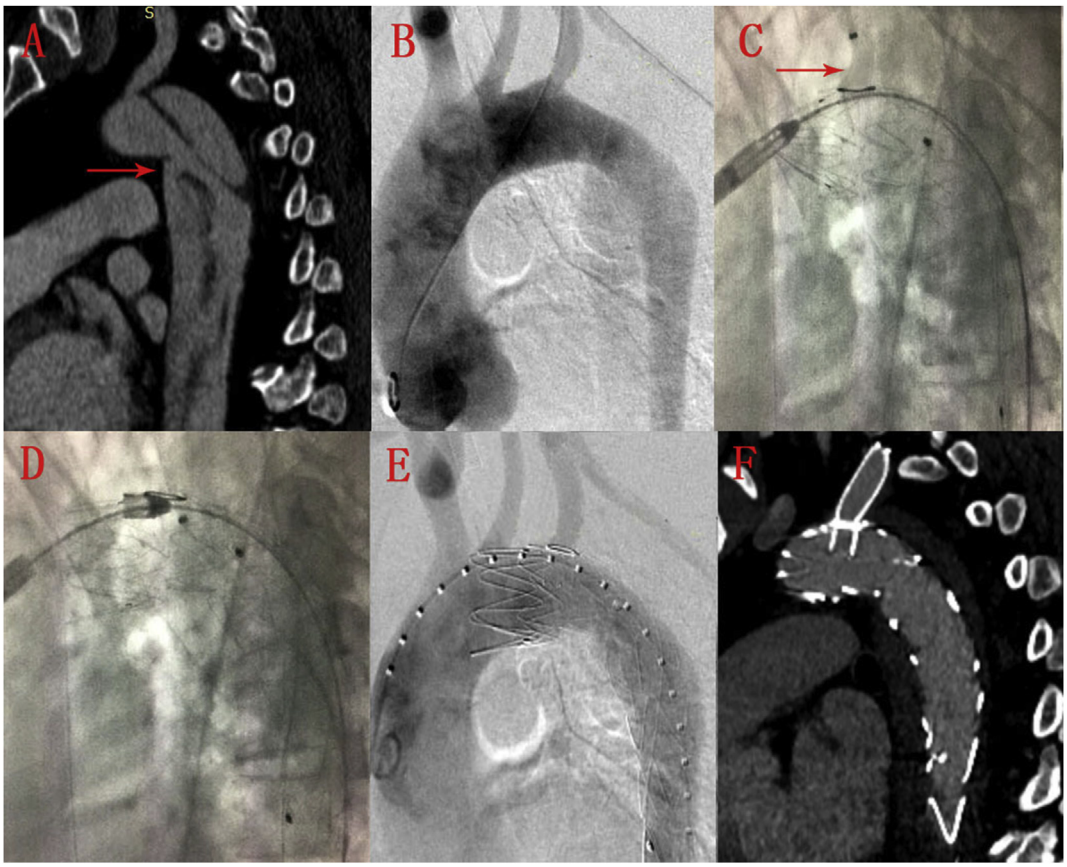

Figure 2. The fenestrated EVAR procedure using the physician modified stent graft. (A) A pre-operative computed tomography scan showing the primary tear entry (red arrow) in the descending aorta and the retrograde dissection extending to the left subclavian artery (LSA). (B) A diagnostic angiogram confirmed the acute type B aortic dissection without healthy proximal landing zone for TEVAR. (C) After ensuring that the fenestration was oriented toward the LSA by hand injection of iodinated contrast through the 6 F sheath placed at the ostium of the LSA (red arrow), the endograft was fully deployed. (D) A catheter and the 6F sheath were then advanced sequentially over the pre-loaded guidewire into the endograft through the fenestration from the retrograde brachial artery access. (E) The LSA alignment uncovered stent (SMART, 10 mm in diameter, 40 mm in length) was deployed. Completion aortography was performed to confirm endograft and LSA fenestration patency without endoleak. (F) One month post-operative CT showing the patency of the LSA and complete thrombosis of the false lumen in the descending aorta.

software (3mensio Vascular, Pie Medical Imaging, Bilthoven, The Netherlands) with centre line luminal reconstructions. In addition, the device sizing, proximal and distal landing zone diameters, and fenestration position were estimated by the pre-operative CTA data.

Device preparation

Procedures were performed in an operating room equipped with a fixed fluoroscopy C-arm. Stent graft modifications were performed on a back table. They were commenced before starting general anesthesia. Thoracic endografts were fully unsheathed on a sterile table. The single LSA fenestration position was marked on the fabric, in line with the radiopaque middle-8-marker of the Valiant device (Medtronic, Eden Prairie, MN, USA) or adjacent to the S-bar (spiral support strut) of both the Relay (Bolton Medical, Sunrise, FL, USA) and the Ankura (Lifetech, Shenzhen, China) devices. The diameter of the LSA fenestration was normally 2 mm smaller than that of the bare or covered stent selected for the LSA, typically 8—10 mm. The fenestration was made using a low temperature ophthalmology cautery (OASIS Medical, Glendora, CA, USA) (Fig. 1A). It was reinforced using the loop of a snare (Amplatz Goose Neck, ev3, Plymouth, MN, USA) and fixed on the fabric with a continuous running suture of CV-5 (Gore, Flagstaff, AZ, USA) (Fig. 1B). A 300 cm, 0.014 inch nitinol guidewire (ASAHI, Nagoya, Aichi, Japan) was used to pass through the LSA fenestration into the endograft, and the stiff tip of the guidewire was pushed about 40 cm into the soft sheath of the Bolton Relay device or the introducer sheath of both the Valiant Medtronic and the Lifetech Ankura device (Fig. 1C and D). The endograft was finally reloaded in the existing sheath using umbilical tape, and the pre-loaded guidewire emerged from under the tip of the introducer sheath (Fig. 1E,G).

Surgical procedures and techniques

Under general anesthesia, an aortogram was performed to confirm the ABAD (Fig. 2A and B). A 300 cm, 0.035 inch guidewire was navigated from the left brachial artery (LBA) through the true lumen of the dissection into the healthy side of the common femoral artery (CFA). The guidewire was exteriorised by a snare (Amplatz Goose Neck, Boston Scientific, Marlborough, MA, USA) to obtain a CFA to LBA through and through platform. A Lunderquist guidewire (Cook Medical, Bloomington, IN, USA) was then introduced into the ascending aorta through the platform. Meanwhile, a 4F multipurpose catheter was delivered parallel to the LBA access, emerging from the CFA.

PMSG was introduced over the Lunderquist guidewire into the common femoral access, and the preloaded guidewire was allowed to move along with the PMSG and exteriorised from the brachial end of the 4F multipurpose catheter in a 55 cm, 6F sheath (Cook Medical) placed earlier in the LBA. When the PMSG was advanced into the descending aorta, the 2 guidewire intertwining was completely removed by rotating the endograft delivery system. Angiograms were obtained in the right and left anterior position to match the clock face orientation of the fenestration to the LSA and to identify the location of the LSA takeoff. First, the parts of the Lunderquist guidewire in the ascending and descending aorta were superimposed under the right anterior oblique (RAO) view. Next, the left anterior oblique (LAO) view, 90° perpendicular to the RAO view was performed to profile the aortic arch. After ensuring that the fenestration was oriented toward the LSA by hand injection of iodinated contrast through the 6F sheath placed at the ostium of the LSA (Fig. 2C), the endograft was fully deployed. The multipurpose catheter was then advanced over the pre-loaded guidewire into the endograft through the fenestration from the retrograde LBA access. The preloaded guidewire was exchanged to a Supercore guidewire (Abbott Vascular, Santa Clara, CA, USA) and the 6F sheath was also advanced into the endograft (Fig. 2D). An uncovered alignment stent can be deployed through the 6F sheath, otherwise a covered alignment stent was implanted passing a larger sheath. Finally, completion aortography was performed to confirm implantation of the PMSG at the intended level and target supra-aortic artery patency without endoleak (Fig. 2E).

Post-operative follow-up

Imaging surveillance of all patients was performed by CTA prior to discharge and at 1, 3, 6, and 12 months after endovascular treatment, to assess patency of PMSGs and aortic branches, endoleak, and dissection exclusion (Fig. 2F).

Statistical analysis

Descriptive statistics were used to describe patient data and outcomes in this cohort.

RESULTS

Patient demographics and presentation

The median patient age was 53 years (range, 18—83 years). Patient demographics and clinical features are shown in Table 1. All patients presented with complicated ABAD with unfavourable proximal landing zones, including inadequate proximal landing zone ($n = 4$), retrograde dissection extending to the LSA ($n = 13$), and retrograde haematoma

Table 1. Patient demographics.

Variables	Mean (range) or percentage ($n = 20$)
Age (years)	53 (18—83)
Male	16 (80.0%)
Comorbid conditions	
Hypertension	18 (90.0%)
Coronary heart disease	7 (35.0%)
Renal insufficiency	3 (15.0%)
Chronic obstructive pulmonary disease	2 (10.0%)
Diabetes mellitus	1 (5.0%)
Peripheral arterial disease	4 (20.0%)
Dyslipidemia	4 (20.0%)
Marfan syndrome	1 (5.0%)

involving the LSA ($n = 3$). The presence of symptoms included lower extremity ischaemia ($n = 3$), visceral malperfusion ($n = 2$), spinal cord ischaemia ($n = 1$), continuous back pain ($n = 7$), and refractory hypertension ($n = 7$). The mean interval between symptom onset and treatment was 5 ± 3 days (range, 1—10 days). Mean operation time was 101 ± 48 min, and fluoroscopy time was 24 ± 16 min.

Stent graft configuration and operative data

The median duration of stent graft modifications was 40 min (range 30—60 min). One single LSA fenestration was created in 19 patients, and one LSA fenestration combined with one LCCA scallop were created in one patient. Twenty PMSGs (Valiant stent grafts, Medtronic, $n = 4$; Relay thoracic stent grafts, Bolton Medical, $n = 10$; Ankura thoracic stent grafts, Lifetech, $n = 6$) were deployed. Multiple endografts were placed in three patients: a Valiant PMSG was placed proximally with a Valiant endograft distally in one patient, a Relay PMSG was placed proximally with a Valiant endograft distally in one patient, and an Ankura PMSG was placed proximally with a Valiant endograft distally in one patient. The combination of a PMSG and bare metal stents was placed in three patients: a Valiant PMSG with two distal bare metal stents (Optimed, Ettlingen, Germany) was deployed in one patient and a Relay PMSG with a distal bare metal stent was deployed in two patients. PMSGs were deployed in Zone 1 ($n = 1$) and in Zone 2 ($n = 19$).

Both covered stents and uncovered stents were used to revascularise the LSA. Covered stents were normally used to avoid endoleak in ABAD patients with the proximal entry tear adjacent to the origin of the LSA, whereas uncovered stents were usually used for those in whom the proximal entry tear was an adequate distance from the LSA, but the retrograde dissection or haematoma extended to the LSA. The LSA alignment uncovered stents (Smart, Cordis, Miami Lakes, FL, USA, $n = 10$; Zilver, Cook Medical, $n = 2$) were placed in 12 patients. The alignment covered stents for the LSA (Viabahn, Gore & Associates, Flagstaff, AZ, USA, $n = 2$ Fluency, C. R. Bard, Murray Hill, NJ, USA, $n = 4$) were implanted in six patients. The alignment stents (a Viabahn covered stent with a Smart bare stent inside) for the LSA were placed in one patient. In another patient, an alignment covered stent (Viabahn) and a chimney bare stent (Scuba, Invatec S.p.A., Roncadelle, Italy) were placed for the LSA and LCCA, respectively. The misaligned LSA in one patient was revascularised instead by performing a chimney bare stent (Smart). Covered stents for the LSA ranged in diameter from 10 to 11 mm and in length from 25 to 50 mm. Uncovered stents for the LSA ranged in diameter from 10 to 12 mm and in length from 25 to 40 mm.

The CFA was accessed to introduce the PMSG in 19 patients, and a right common iliac conduit was required in one patient as a result of delivery failure from the CFA. The LBA was accessed percutaneously for deployment of the LSA bare stent in 14 patients, with open left brachial artery exposure needed for the LSA covered stent in four patients. CFA access was required to place the LSA covered stent in the remaining two patients because of delivery failure from the exposed LBA. The reason for LSA stent delivery failure from brachial access in the two cases in this study was incorrect fenestration orientation.

Peri-operative outcomes and complications

The technical success rate was 90% (18 of 20), with precise placement of the PMSG, maintenance of branch perfusion, and absence of endoleak. Partial coverage of the LCCA after placement of the PMSG occurred in one patient, and a chimney stent had to be implanted in the LCCA to maintain LCCA perfusion. Partial LCCA coverage was not due to too proximal deployment of the PMSG or creation of the fenestration too far from the proximal edge of the endograft. The reason was that the clock face position of the scallop for LCCA was located slightly more posteriorly than planned after the deployment of the PMSG, from 12:00 to about 12:30. Type III endoleak between the LSA covered stent and the PMSG occurred in this patient 1 week post fTEVAR owing to the bigger fenestration created than scheduled, and was resolved after re-intervention with deployment of an Amplatzer occluder device across the site of the leak. A chimney stent was deployed to correct the misalignment of the LSA in another patient. The leak from the fenestration was occluded with a thoracic cuff endograft deployed inside the fenestrated endograft. The diameter of the thoracic cuff endograft was 2 mm larger than that of the PMSG. Stent induced new entry (SINE) occurred at the distal edge of the PMSG in one patient, which was diagnosed by an aortogram after deployment of the PMSG. An overlapping Valiant endograft without proximal bare stent was deployed distally to seal the new entry.

The symptoms of visceral ischaemia in two cases (1 coeliac and 1 SMA) and lower extremity ischaemia in three cases improved after the expansion of the true lumen. Spinal cord ischaemia in one case recovered after blood pressure manipulation and glucocorticoid therapy for 5 days post-operatively. There were no peri-operative neurological complications and no deaths. The median length of stay was 9 ± 6 days (range, 5—26 days). LBA pseudoaneurysm at the puncture site was found post-operatively in one patient (Patient 16) and open repair was required. Renal deterioration occurred post-operatively in one patient who had renal dysfunction pre-operatively. The renal function of this patient recovered uneventfully with conservative therapy.

Follow-up

The median duration of follow-up was 6.95 months (2—14 months). All the patients survived. There was 100% primary patency for the LSA stents. Endoleak occlusion of the patient was confirmed by CTA during the follow-up period. There were no fenestration related Type I or III endoleaks. None of the patients reported neurological complications at the follow-up examination. Thrombosis in the aortic false lumen of the PMSG exclusion segment was observed in all the patients.

DISCUSSION

LSA coverage during TEVAR is necessary to obtain a healthy proximal sealing zone in patients suffering from ABAD with pathologies involving the distal aortic arch. However, increased experience has shown that LSA coverage is associated with an increased risk of arm ischaemia, vertebral territory and anterior circulation stroke, and paraplegia.[11,12] Routine revascularisation of the LSA was recommended by the Society for Vascular Surgery Committee on Aortic Disease in 2009.[13]

There is a wide variety of strategies proposed to revascularise the LSA during TEVAR, including open elective bypass to, or transposition of, the LSA or deployment of branch stents during the fTEVAR or branched TEVAR.[14,15] In order to minimise or eliminate the potential risks associated with complex open reconstruction of the LSA, branch vessel stent placement was recommended.[16] Custom made fenestrated or branched endografts, which require extensive planning with precise pre-operative imaging and long manufacturing delays, are not feasible for patients with ABAD in acute or subacute settings. Redlinger et al.[17] have described the technique of in situ laser fenestration of the endograft to revascularise the LSA during emergency TEVAR. This technique has some limitations for dissection or aneurysmal disease involving the LSA. The experience of fTEVAR using PMSGs for the treatment of patients with ABAD to revascularise the LSA in emergency situations has been described.

The pathologies of the patients in this study included dissections with the proximal entry tear in the immediate vicinity of the orifice of the LSA and descending aortic dissections with retrograde aortic dissection or retrograde haematoma extending to the LSA. The aortic wall involved in the dissection or haematoma is too fragile to be used as the proximal landing zone for TEVAR. The unfavourable proximal landing zone might increase the risk of dissection rupture or a new retrograde dissection extending to the aortic arch, even into the ascending aorta. TEVAR for ABAD is particularly prone to retrograde type A aortic dissection, which is associated with devastating outcomes.[18] An appropriate proximal landing zone for TEVAR is defined both by its adequate length and its healthy vessel wall.

Pre-operative CTA is very helpful for the pre-operative planning of the stent graft modification. The distance between the branches of the aortic arch and the clock position of each supra-aortic branch can be measured. Moreover, the diameters of the landing thoracic aorta and branches, location of the vertebral artery takeoff from the LSA, and optimal C-arm projection for the LSA with tangential view can be obtained pre-operatively.

Three kinds of endografts for f-TEVAR were chosen from experience, including the Medtronic Valiant stent graft, Relay thoracic stent graft, and Ankura thoracic stent graft. About 10—15% oversized and 200 mm length endografts were used for all 20 cases. Some differences were found during the procedures of graft modification and implantation. The material of the Relay thoracic graft is more suitable for fenestration because of its thickness and tear resistance. The Relay thoracic stent graft was much easier to reload than other two. Moreover, the fenestration marker of the Relay thoracic stent graft can be seen more clearly when the soft delivery sheath is advanced into the aortic arch outside the outer sheath. Otherwise, owing to the poor support of the soft delivery sheath, the Relay thoracic stent graft is normally considered unsuitable for use in certain settings, including aortic arch aneurysms that are too tortuous or in serious tortuosity of the aortic arch. Thus, the Medtronic Valiant stent graft or Ankura thoracic stent graft is recommended in the settings described above. Sometimes, in consideration of the low medical cost to the patient, the Ankura thoracic stent graft was chosen.

The main concern expressed during the PMSG deployment procedure was orientation of the LSA fenestration, which is very difficult in a heavily diseased or severely angulated arch. Some tips for fTEVAR positioning and orientation may help. First, it is necessary to avoid wrapping of the wire around the tapered tip of the delivery system as the PMSG is advanced into the aortic arch. Rotation (clockwise or counterclockwise) of the delivery system should be performed in the mid-descending aorta when intertwining between the pre-loaded guidewire and the Lunderquist guidewire occurs. Next, the LSA fenestration marker should be oriented toward the ostium of the LSA under both LAO and RAO angulations for longitudinal positioning and clock positioning. Finally, traction on the exteriorised end of the pre-loaded guidewire may help orientation of the fenestration towards the LSA, even if orientation of the fenestration is not so accurate. Proper orientation of the LSA fenestration will facilitate alignment of the endograft to the target vessels.

The pre-loaded guidewire may lead to injury to the LSA takeoff during stent graft deployment. Some details of technical manoeuvres should be described to avoid injury to the aorta arch. First, the pre-loaded guidewire should be protected with a catheter when the delivery system is rotated to avoid the guidewire intertwining and wire wrap in the mid-descending aorta. Second, it is very important to keep moderate tension on the pre-loaded wire during the procedure to align the fenestration with the LSA ostium. Finally, it is best to withdraw the pre-loaded guidewire and protective catheter together when problems occur.

The limitations of this study include its retrospective nature, the small sample size, the short follow-up interval, and the lack of a control group of cases undergoing hybrid surgery with TEVAR combined with carotid—subclavian bypass for a direct comparison of the efficacy and safety between the two approaches. Another limitation is the absence of bench testing of PMSGs prior to clinical use. The issue of late fenestration related endograft integrity may be related to the feasibility of the on table f-TEVAR technique.

An encouraging early result of using PMSGs for the treatment of patients with ABAD with an unfavourable landing zone for TEVAR was obtained. Acceptable re-intervention and complication rates were also described. The favourable peri-operative morbidity and mortality in

this series indicated the feasibility of this technique. Long-term follow-up is necessary to better determine the durability of this technique.

CONCLUSIONS

fTEVAR with PMSGs may be a viable alternative for ABAD patients with an unfavourable proximal landing zone, unable to wait for a custom made fenestrated or branched device. Short-term outcomes based on this study seem to be acceptable. Further studies in a larger case series and longer follow-up are needed to better prove the durability of this technique.

CONFLICT OF INTEREST

None.

FUNDING

None.

REFERENCES

1 Luebke T, Brunkwall J. Type B aortic dissection: a review of prognostic factors and meta-analysis of treatment options. *Aorta (Stamford)* 2014;**2**:265—78.
2 Steuer J, Eriksson MO, Nyman R, Björck M, Wanhainen A. Early and long-term outcome after thoracic endovascular aortic repair (TEVAR) for acute complicated type B aortic dissection. *Eur J Vasc Endovasc Surg* 2011;**41**:318—23.
3 Clough RE, Mani K, Lyons OT, Bell RE, Zayed HA, Waltham, et al. Endovascular treatment of acute aortic syndrome. *J Vasc Surg* 2011;**54**:1580—7.
4 Rehman SM, Vecht JA, Perera R, Jalil R, Saso S, Kidher E, et al. How to manage the left subclavian artery during endovascular stenting for thoracic aortic dissection? An assessment of the evidence. *Ann Vasc Surg* 2010;**24**:956—65.
5 Lee TC, Andersen ND, Williams JB, Bhattacharya SD, McCann RL, Hughes GC. Results with a selective revascularization strategy for left subclavian artery coverage during thoracic endovascular aortic repair. *Ann Thorac Surg* 2011;**92**:97—102.
6 Roselli EE, Arko FR, Thompson MM. Results of the Valiant Mona LSA early feasibility study for descending thoracic aneurysms. *J Vasc Surg* 2015;**62**:1465—71.
7 Kasemi H, Marino M, Di Angelo CL, Fadda GF, Speziale F. Aortic arch and descending thoracic aortic saccular aneurysms treatment with fenestrated endograft and chimney technique for aortic branch rescue. *Ann Vasc Surg* 2015;**29**:126.e15—9.
8 Murphy EH, Dimaio JM, Dean W, Jessen ME, Arko FR. Endovascular repair of acute traumatic thoracic aortictransection with laser-assisted in-situ fenestration of a stent-graft covering the left subclavian artery. *J Endovasc Ther* 2009;**16**:457—63.
9 Joseph G, Premkumar P, Thomson V, Varghese M, Selvaraj D, Sahajanandan R. Externalized guidewires to facilitate fenestrated endograft deployment in the aortic arch. *J Endovasc Ther* 2016;**23**:160—71.
10 Yuri K, Yokoi Y, Yamaguchi A, Hori D, Adachi K, Adachi H. Usefulness of fenestrated stent grafts for thoracic aortic aneurysms. *Eur J Cardiothorac Surg* 2013;**44**:760—7.
11 Buth J, Harris PL, Hobo R, van Eps R, Cuypers P, Duijm L, et al. Neurologic complications associated with endovascular repair of thoracic aortic pathology: incidence and risk factors. A study from the European Collaborators on Stent/Graft Techniques for Aortic Aneurysm Repair (EUROSTAR) Registry. *J Vasc Surg* 2007;**46**:1103—11.
12 Chung J, Kasirajan K, Veeraswamy RK, Dodson TF, Salam AA, Chaikof EL, et al. Left subclavian artery coverage during thoracic endovascular aortic repair and risk of perioperative stroke or death. *J Vasc Surg* 2011;**54**:979—84.
13 Matsumura JS, Lee WA, Mitchell RS, Farber MA, Murad MH, Lumsden AB, et al. The society for vascular surgery practice guidelines: management of the left subclavian artery with thoracic endovascular aortic repair. *J Vasc Surg* 2009;**50**:1155—8.
14 Lu Q, Jing Z, Zhao Z, Bao J, Feng X, Feng R, et al. Endovascular stent graft repair of aortic dissection type B extending to the aortic arch. *Eur J Vasc Endovasc Surg* 2011;**42**:456—63.
15 Tsilimparis N, Debus ES, von Kodolitsch Y, Wipper S, Rohlffs F, Detter C, et al. Branched versus fenestrated endografts for endovascular repair of aortic arch lesions. *J Vasc Surg* 2016;**64**:592—9.
16 Cires G, Noll Jr RE, Albuquerque Jr FC, Tonnessen BH, Sternbergh WC. Endovascular debranching of the aortic arch during thoracic endograft repair. *J Vasc Surg* 2011;**53**:1485—91.
17 Redlinger Jr RE, Ahanchi SS, Panneton JM. In situ laser fenestration during emergent thoracic endovascular aortic repair is an effective method for left subclavian artery revascularization. *J Vasc Surg* 2013;**58**:1171—7.
18 Riambau V, Böckler D, Brunkwall J, Cao P, Chiesa R, Coppi G, et al. Editor's Choice-Management of Descending Thoracic Aorta Diseases: Clinical Practice Guidelines of the European Society for Vascular Surgery (ESVS). Society for Vascular Surgery (ESVS). *Eur J Vasc Endovasc Surg* 2017;**53**:4—52.