

- 19 Khwaja A. KDIGO clinical practice guidelines for acute kidney injury. *Nephron Clin Pract* 2012;120:179–84.
- 20 Azéma L, Davaine JM, Guyomarch B, Chaillou P, Costargent A, Patra P, et al. Endovascular repair of common femoral artery and concomitant arterial lesions. *Eur J Vasc Endovasc Surg* 2011;41:787–93.
- 21 Sinci V, Kalaycioglu S, Halit V, Gökğöz L, Soncul H, Ilgit E, et al. Long-term effects of combined iliac dilatation and distal arterial surgery. *Int Surg* 2000;85(1):13–7.
- 22 Aburahma AF, Robinson PA, Cook CC, Hopkins ES. Selecting patients for combined femorofemoral bypass grafting and iliac balloon angioplasty and tenting for bilateral iliac disease. *J Vasc Surg* 2001;33(2). S93–9.
- 23 Kim Min Su, Joo Yoon Sung, Park Ki Hyuk. Results of simultaneous hybrid operation in multi-level arterial occlusive disease. *J Korean Surg So* 2010;79:386–92.

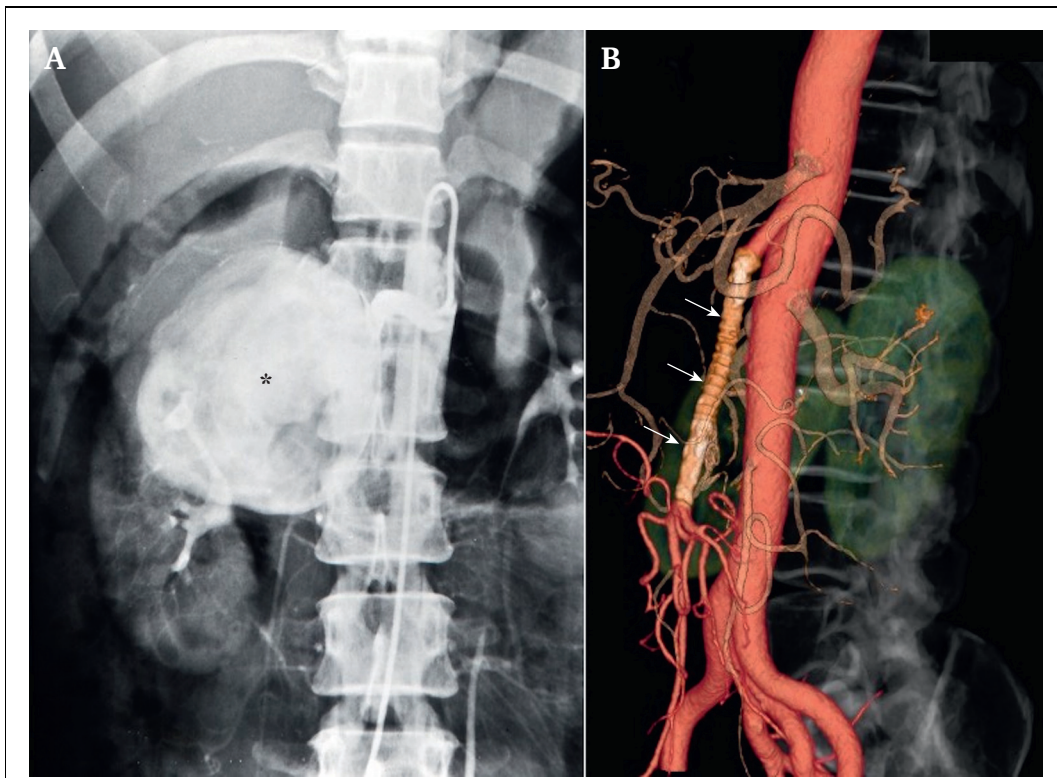
Eur J Vasc Endovasc Surg (2022) 63, 565

COUP D'OEIL

Prosthetic Superior Mesenteric Artery Bypass Patent After 32 Years

Naoki Fujimura^{*}, Koza Ishitobi

Department of Vascular Surgery, Saiseikai Central Hospital, Tokyo, Japan



A 37 year old woman with a history of blunt abdominal trauma during childhood complained of epigastric pain. At that time, computed tomography (CT) and selective angiography (A) revealed a 10 cm unruptured aneurysm of the superior mesenteric artery (asterisk; A). The aneurysm was resected and replaced by a great saphenous vein bypass. The colour of the bowel did not improve, so a reinforced 6 mm polytetrafluoroethylene graft was used. Aspirin was discontinued after one year and the patient was lost to follow up. After 32 years, when the patient was 69 years old, the CT scan showed a patent prosthetic bypass (white arrows; B).

* Corresponding author. Department of Vascular Surgery, Saiseikai Central Hospital, 1-4-17 Mita, Minato-ku, Tokyo 108-0073, Japan.

E-mail address: naokif0212@gmail.com (Naoki Fujimura).

1078-5884/© 2022 European Society for Vascular Surgery. Published by Elsevier B.V. All rights reserved.

<https://doi.org/10.1016/j.ejvs.2022.01.003>